

Convergence Insufficiency

Manish Agrawal, M.S, Manish Sharma M.S, Suma Ganesh M.S

Introduction

Convergence is a disjugate movement in which both eyes move inwards so that the lines of sight intersect in front of the eyes. It allows bifoveal single vision to be maintained at any fixation distance. It does not deteriorate with increasing age as the accommodation.

Types of Convergence

(1) Voluntary Convergence – Amount of Convergence of visual axes that can be produced at will

(2) Reflex convergence - Convergence of visual axes which is not under complete voluntary control and it has four components –

- a. Tonic convergence – Due to inherent innervational tone of extra ocular muscles.
- b. Fusional convergence -The convergence that is produced to ensure that similar retinal images are projected on to corresponding retinal areas
 - i. It is initiated by bitemporal retinal image disparity
 - ii. Normal fusional convergence amplitude for distance is about 14- 18D and for near 35-40 D
- c. Accommodative convergence – That component of convergence which occurs when the eyes accommodate stimulated by blurred image
- d. Proximal convergence - component of convergence which is induced by proximity of the object

Convergence Insufficiency

Convergence insufficiency (CI) is a common condition that is characterized by a person's inability to maintain proper binocular eye alignment on objects as they approach from distance to near. The symptoms associated with convergence insufficiency vary from mild to severe, but they are often extremely troublesome for those patients with this condition, especially when associated with a small angle exotropia at the near working distance. It affects 3 – 5% of the population. This is the most common cause of ocular discomfort and muscular asthenopia and common age group is 15 to 25 yrs.

Department of Pediatric Ophthalmology and Strabismus

Dr. Shroff's Charity Eye Hospital,
Daryaganj, New Delhi

Characteristics

1. Symptoms due to muscular fatigue
 - ♦ Frontal headache
 - ♦ Eye strain
 - ♦ Difficulty in changing focus from distance to near object
2. Symptoms due to failure to maintain fusion
 - ♦ Blurred near vision & crowding of words while reading
 - ♦ Intermittent crossed diplopia for near vision under fatigue condition characteristically one eye will be closed or covered while reading
3. Pt. may have an exophoria for near with smaller exophoria, esophoria or orthophoria for distance.
4. Convergence Fusional amplitude will be low
5. Near point of convergence is usually receded but may be within normal range(6-8 cm) also
6. Patients may have reduced stereo acuity at near.
7. Normal near point of accommodation may be present in many patients

Diagnosis

Diagnosis of convergence insufficiency = Asthenopic symptoms + reduced amplitude of convergence

Examination

Cover test

May show a slight exo or esophoria at near with slow or delayed recovery.

Alternate cover test

Prolonged ACT should be performed to elicit any underlying esophoria that becomes apparent on extreme dissociation.

Duction and version test

Any under-action of adduction or a small vertical deviation may cause decrease in convergence.

Near point of convergence test

- ♦ CI said to exist if NPC is more than 10 cm.
- ♦ Not very reliable diagnostic test because in presence

of normal NPC, CI may exist due to abnormal fusional amplitude.

- ♦ Can be done by RAFrule/Prince rule

Drop convergence test

To test the ability of the patient to maintain the convergence.

Near point of accommodation test

- ♦ Measurement of NPA is essential in each case to diagnose and manage in patients with combined insufficiency of convergence and accommodation.
- ♦ It should be tested with full refractive correction.
- ♦ It should be done first in either eye and then with both eyes open.
- ♦ Uniocular results will be better than the binocular if CI is present.

Occasionally the amplitude of accommodation is also reduced if there is an associated accommodation insufficiency present

Fusional amplitude test

Measurement of amplitude convergence

- ♦ Prism bar method
- ♦ Synaptophore method

Prism bar method

The Patient is asked to fixate 6/12 symbol at 33 cm and the BO prism bar is used with increasing the power of BO prism with bifoveal single vision i.e. up to the point when the patient just appreciate diplopia. This point is the end point of the test and is called break point. The break point will be the fusional convergence amplitude.

The low readings are indicative of insufficiency.

At this point the power of the prism is decreased slowly until he again fuses. This point is called recovery point.

Patch test

To differentiate between CI and accommodation insufficiency.

Sensory fusion and stereopsis should also be tested

Classification & etiology of CI

Primary CI – CI not due to strabismus or refractive error

Predisposing factors -

1. Wide interpupillary distance
2. Exophthalmos

3. Uniocular occupation e.g. watch maker

Other factors are –

- ♦ Head trauma
- ♦ Diphtheria
- ♦ Encephalitis
- ♦ Parkinson disease
- ♦ Thyroid eye disease

Precipitating causes

- ♦ Ocular fatigue
- ♦ Recent prolonged near work
- ♦ Poor lighting
- ♦ Night driving

Secondary CI – caused by an associated refractive error or strabismus

Refractive errors - CI may be associated with high hypermetropia and myopia

High hypermetropes – no effort to accommodate and there is deficient accommodative convergence as well

Myopes - may not need accommodation and thus lack accommodative convergence.-

Presbyopes – with the advent of presbyopia, near point recedes and so there is less use of convergence.

- ♦ If left uncorrected CI sets in.
- ♦ CI may develop with first time use of presbyopic correction.

Strabismus - Extra ocular muscle imbalance in the form of

- ♦ Exophoria,
- ♦ Intermittent exotropia and
- ♦ Vertical muscle imbalance, if left untreated for long time may be associated with CI

Limitation in adduction of one or both eye, which affects the ability to converge, e.g. surgically weakened MR or Duane's syndrome type 2,3

Drugs -Over 100 drugs have been reported to decrease accommodation i.e. analgesics, antibacterials, anti-spasmodics, anti-histamines, diuretics, amphetamines, cocaine and marijuana.

Management of convergence insufficiency

- ♦ CI has excellent prognosis in majority of cases
- ♦ Children are treated – when fusion vergence are poor and are showing signs of becoming exotropic.
- ♦ Adults – receive treatment in presence of symptoms
- ♦ The three modalities of treatment are:

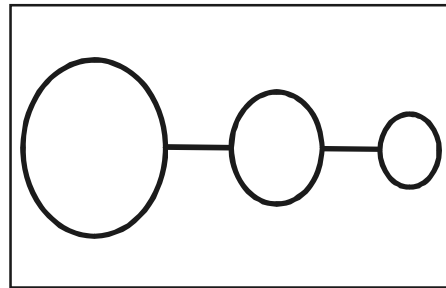
A. Optical treatment

- ♦ Appropriate spectacle correction should be the first

step

- ♦ For myopes – full correction should be given
- ♦ For hyperopes – under-correct to stimulate their accommodation, which will simultaneously stimulate the convergence.

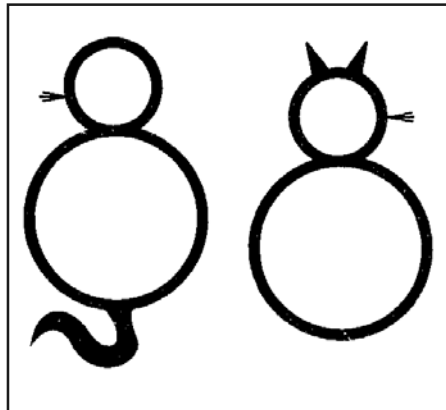
In adults above 40 yrs proper presbyopic correction should be done.



Exercise using convergence card

Prismotherapy

- ♦ When all the exhaustive Orthoptic exercises fail
- ♦ Base in prism – can be incorporated in near range glasses or bifocals in order to relieve symptoms.
- ♦ This should not be the primary treatment because of tendency of exo-deviation to gradually increase with wear of base in prisms.



Exercise using stereogram cards

B. Orthoptic treatment

Mainstay of treatment of CI.

Because of the plasticity of the fusional convergence reflex, fusional convergence amplitude can be increased by challenging the binocular vision by two ways –

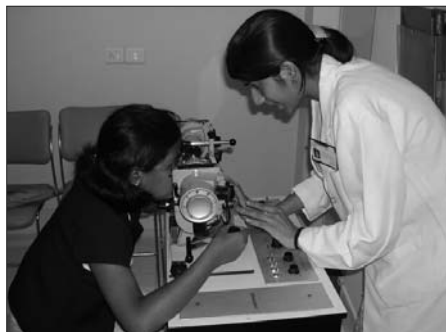1. Enlisting voluntary convergence to facilitate fusional convergence
2. Provoking fusional convergence by stimulating disparate retinal elements

Enhancement of voluntary convergence is accomplished through a variety of visual tasks e.g.

Advancement exercise: advancing a simple visual target at increasingly closer range while maintaining single binocular vision at as close as possible

Enhancement of fusional convergence is accomplished through the use of base out prism

- ♦ Target advancement exercise with base out prism
- ♦ Base out prism can also be utilized for prescribed periods during common visual activities such as reading and computer use while maintaining single binocular vision.



Convergence exercise with Synaptophore

The response to Orthoptic therapy is clinically monitored by interval measurements of fusional convergence amplitude and NPC

The success of Orthoptic therapy in CI is high.

A 72% cure rate and 19% improved rate were reported by Grisham (1998)

C. Surgery

Reserved for the patients with large exo-deviation at near vision.

B/L MR resection – first reported by Von Noorden (1976)

Haldi (1978) described 6 cases and Hermon (1981) described 14 cases.

Von Noorden & Hermon advocated this treatment and reported subjective relief of symptoms in all cases.

Haldi reported subjective relief of one case after 30 months of follow up.

Suggested Reading

1. Cooper J, Duckman R: Convergence insufficiency: Incidence, diagnosis and treatment *J Am Optom Assn* 1978; 49:673-680
2. Daum K: Characteristics of convergence insufficiency. *Am J Optom Physiol Optics* 1988; 65:426-438
3. Shippman R, Infantino J, Cimbold D, Cohen KR: Convergence insufficiency with normal parameters. *J Pediatr Ophthalmol Strabismus* 1983; 20:158-161
4. Prakash P, Agarwal LP, Nag SG: Accommodational weakness and CI. *Orient Arch Ophthalmol* 1972; 10:261-264.
5. Mazow ML, France TD, Finkleman S, Frank J, Jenkins P: Acute accommodative and convergence insufficiency. *Trans Am Ophth Soc*; 1989:158-173.
6. Von Noorden GK. Binocular vision and ocular motility. St. Louis, CV Mosby 1996, pp 469-472
7. Von Noorden GK. Brown DJ, Parks M: Associated convergence insufficiency. *Trans Am Ophthal Soc*; 1989:158-173
8. Brinkley JR, Walonker F: convergence amplitude insufficiency. *Ann Ophthalmol* 1983; 15:826-831
9. Von Noorden GK. Binocular Vision and Ocular Motility, St. Louis, CV Mosby 1996, pp 197
10. Narbheram J, Firth AY: Prism Fusion Range: Blur point, break point, and recovery point. *Brit Orthopt J* 1997; 54:2-6

Mooren's Ulcer

M. Vanathi, MD, Panda A, MD, Khokhar S, MD

Mooren's ulcer was first described by Bowman in 1849¹. Mckenzie², in 1954 described the chronic serpiginous ulcer or *ulcus rodens* of the cornea. Mooren's³ in 1967 provided a detailed report of 3 clinical cases and hence his name came to be associated with the disease. A type III hypersensitivity mechanism has been implicated in the etiopathogenesis of Mooren's ulcer. The pathogenesis of the Mooren's ulcer closely resembles that of peripheral ulcerative keratitis (PUK) associated with classic type III immune complex systemic diseases such as Rheumatoid arthritis and polyarthritidis nodosa.

Epidemiological features of and clinical characteristics

The incidence of Mooren's ulcer is not well documented but it is known to be rare. Lewallen and Courtright⁴ reported that men were 1.6 times more likely to have Mooren's ulcer than women and that 43% of older patients had bilateral disease whereas had bilateral disease only one third of patients younger than 35 years of age. Wood and Kaufman⁵ classified the disease into 2 groups according to the age of onset. 67% of the cases were unilateral and 33% were bilateral. Type I disease was benign and usually unilateral with mild to moderate symptoms. This type occurs in the elderly and usually responds well to medical and surgical treatments. The second type, more likely to be bilaterally with relatively more pain and generally poor response to therapy, occurs in young patients (malignant type).

Bilaterality rate of 25% of cases of benign type was found mostly in patients over the age of 35 and no racial difference has been observed⁶. The bilaterality rate of 75% of cases of the malignant type was seen mostly in black patients younger than 35. Walron⁷ divided the disease into 3 types based on the clinical presentation and anterior segment fluorescein findings as unilateral Mooren's ulcer, bilateral aggressive Mooren's ulcer and bilateral indolent Mooren's ulcer. Reported rate of Mooren's ulcer varies from 13.3%¹⁰ to 36%¹¹.

Definition

Mooren's ulcer by definition is a chronic peripheral ulcerative keratitis of the cornea in the absence of any diagnosable systemic disorder with a steep, central, leading edge that starts in the periphery and progresses centrally or circumferentially to involve the entire cornea.

Pathogenesis

Autoimmunity is suspected to be involved in the pathogenesis of Mooren's ulcer based on evidence of circulating antibodies¹²⁻¹⁴ to the corneal stroma and specific cell mediated immune reaction toward a partially purified corneal antigen (Co-Ag). The triggering factor instigating this autoimmune response is not clearly known. Privileged corneal antigens may become the target of the patient's immune system by local exposure of these antigens due to corneal trauma, surgery or infection. It has been proposed that pathogens such as a helminths stimulate the production of antibodies that cross-react with corneal antigens. Despite evidence of humoral and cell mediated immune mechanisms that are present in Mooren's ulcer, the exact pathogenesis of the disease remains unknown.

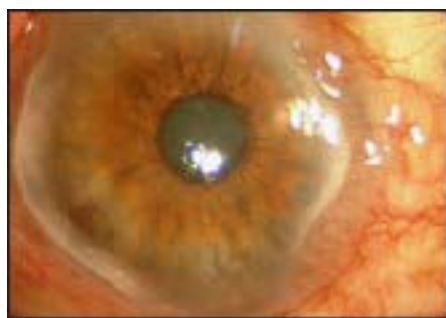

Fig.1: Characteristic appearance of an eye with ulcer

Clinical features

Patients with Mooren's ulcer will present with redness, increased lacrimation and photophobia, but pain is typically the outstanding feature. The pain is excruciating and may seem well out of proportion to the corneal inflammation. Decreased visual acuity may be secondary to associated iritis, irregular astigmatism due to the peripheral corneal thinning. The disease may begin as several patchy peripheral stromal infiltrates that then coalesce, commonly in the region of the palpebral fissure. Generally there is involvement upto the limbus. The ulcerative process spreads circumferentially and then centrally to involve the entire cornea eventually. The anterior 1/3 to 1/2 of the stroma is involved characteristically with a steep overlying central and leading edge. It is difficult to adjudge the depth of the involvement unless the lesion is gently probed at the overlying edges. Healing and vascularization occurs slowly with the disease running a chronic course over 4-18 months. Portions of the ulcer may be quiescent while the

Table 1: Differential diagnosis of PUK

	<i>Infections</i>	<i>Non infections</i>
Ocular	<ul style="list-style-type: none"> ◆ Bacterial (Staphylococcus, Streptococcus, Moraxella, haemophilus goncocus) ◆ Viral (Herpes simplex, herpes zoster) ◆ Acanthamoeba ◆ Fungal 	<ul style="list-style-type: none"> ◆ Mooren’s ulcer ◆ Terrien’s marginal degeneration ◆ Pellucid marginal degeneration ◆ Blepharitis ◆ Keratoconjunctivitis sicca ◆ Neurotrophic and Neuroparalytic ◆ Nutritional deficiency ◆ Ocular chemical injury ◆ Contact lens ◆ Trauma ◆ Post-surgical
Systemic	<ul style="list-style-type: none"> ◆ Tuberculosis ◆ Syphilis ◆ Varizella zoster ◆ gonorrhoea ◆ human immunodeficiency virus 	<ul style="list-style-type: none"> ◆ Rheumatoid arthritis ◆ Giant cell arthritis ◆ Wegener’s granulomatosis ◆ Systemic lupus arthematis ◆ Bacillary dysentery ◆ Sjogren’s syndrome ◆ Relapsing polychondritis ◆ Progressive systemic sclerosis ◆ Churg-Stress syndrome ◆ Crohn’s disease ◆ ulcerative cohitis ◆ Rosacea ◆ Steven Johnson’s syndrome ◆ Sarcoidosis ◆ Behcet’s disease ◆ Psoriasis ◆ Malignancy ◆ Cryoglobulinemia ◆ Schonlein-Henoch purpose ◆ Serum sickness ◆ Pyoderma gangrenosum ◆ Erythema devatum diutinum

Perforation is rare, though it can occur, especially following trauma.

Diagnosis

Table 1 outlines the differential diagnosis of peripheral ulcerative keratitis (PUK). Laboratory investigations to rule out several systemic diseases leading to PUK are mandatory. These include immunology and dermatology workup, X-ray chest and sinus X-ray, Mantoux, hemogram, liver and renal function tests, Rheumatoid factor, autinuclear antibody (ANA),antineutrophil cytoplasmic antibody (ANCA), complement fixation, angiotensin converting enzyme, VDRL, hepatitis B, hepatitis C and HIV antigen detection, immunocomplex tests, serum protein electrophoresis and stool examination. Scrapings for microbial investigations to rule out infectious cause or secondary infection must be performed.

Treatment

The several treatment modalities tried for Mooren’s ulcer include subconjunctival mercury dichloride, tincture of iodine, carbonic and nitric acid formalin, trichloroacetic acid, subconjunctival heparin and mercury cyanide. Other procedure like galvanocautery, irradiation, paracentesis, vitamin B₁ injections and tuberculin infections, delimiting keratotomy, plasma exchange, goretex patch grafting and periosteal grafting have also been tried in the management of Mooren’s ulcer.

Management of Mooren’s ulcer can be subdivided into medical or surgical therapy modalities.

remaining may be active. The end stage is a typical scarred, vascularised thinned cornea with the patient experiencing sudden relief from the excruciating pain.

Adjacent conjunctiva may be inflamed and edematous iritis is sometimes associated with Mooren’s ulcer. Hypopyon is rare unless secondary infection is present. Glaucoma and cataract may complicate the process.

Medical Management

Topical steroids

Initial therapy includes topical prednisolone acetate 1% hourly along with cycloplegics and prophylactic antibiotics. Gradual tapering of topical steroids over a period of results is done during the healing course of the

disease. It is imperative to maintain the patient on topical dilute steroids over a prolonged period. Topical steroid therapy is beneficial in the benign form of the disease. Use of oral pulse steroids (60-100mg of oral prednisolone) has been advocated where topical therapy is ineffective for over 10 days or in case of deep ulcers. Topical tetracycline, medroxy progesterone 1% may be used because of their acute collagenolytic properties. A therapeutic bandage contact lens may be used in the conjunctiva along with topical therapy.

Surgical management modalities include

1. Limbal conjunctivectomy/resection

Conjunctival resection is required if the ulcer progresses despite steroid therapy. Healing of Mooren's ulcer after excision and recession of the adjacent limbal conjunctiva has been based on the beneficial effect provided by the removal of proteolytic conjunctival enzymes, the inflammatory cells that produce antibodies against the cornea and the cytokines which enhance inflammation and bring in additional inflammatory cells. A wide conjunctival resection to base sclera, extending to at least 2 clock hours on either side of the ulcer and 4 mm posteriorly has been recommended. The use of peritomy and cryoapplication has also been advocated.

Keratoepithelioplasty

In keratoepithelioplasty several fresh donor corneal lenticules with intact epithelium are placed near the distal side of the ulcerated area and securely sutured on the bare sclera with two 10.0 nylon interrupted sutures. The lenticules are thought to form a biological barrier between host cornea and reepithelialising conjunctiva and its immune components. This can be combined with corneoscleral lamellar graft. The beneficial effects of keratoepithelioplasty are unclear and we do not perform this procedure.

Superficial Keratectomy

Resection of the overhanging lip of the ulcerating cornea and application of tissue adhesive with bandage soft contact lens application or amniotic membrane has been described.

Keratoplasty

Rehabilitative surgical therapy in two stages, namely initial lamellar tectonic grafting followed by central penetrating keratoplasty may be required in advanced cases. LKP is the most widely practiced surgery at present. It removes antigenic targets of the cornea, prevents immunological reactions, reconstructs the anatomical

structure, prevents perforation and improves vision. The principle of lamellar keratoplasty surgery in Mooren's ulcer is to remove necrotic ulcerative cornea and to reconstruct the anatomical structure of the cornea. For an ulcer smaller than half circle of the limbus and the central 7-8 mm of the cornea uninvolved *crescent shaped lamellar graft* can be used. For an ulcer larger than 2/3 of a circle of the limbus where the central 7-8 mm of cornea is intact, a *doughnut shaped lamellar graft* is recommended. A *full lamellar graft* is used to maintain useful vision. Double lamellar grafts (a fresh thin inner graft with corneal endothelial cells is used to repair the perforation, on which another lamellar graft shaped in accordance with the shape of the ulcer is placed) can be used for perforations of the peripheral cornea. Postoperative use of topical steroids and 1% cyclosporine A provides excellent treatment effect in all cases.

Small perforation may be managed with cyanoacrylate glue applications with bandage contact lens application. It is to be remembered that the prognosis of a tectonic graft in Mooren's ulcer in the presence of active inflammation is poor.

Immunosuppressive therapy

Systemic immunosuppression

Systemic immunosuppression is indicated in cases of bilateral relentlessly progressive Mooren's ulcer not responding to previous therapeutic modalities.

- a. Cyclophosphamide (2 mg/kg/d)
- b. Methotrexate (7.5-15 mg weekly)
- c. Azothioprine (2 mg/kg/d)
- d. Cyclosporine A (loading dose of 8 mg/kg in two divided doses for 2 days, thereafter being reduced to 3-4 mg/kg/d to maintain serum level of 200-400 ng/ml).

Topical cyclosporin A

Use of topical cyclosporin A is recommended in bilateral progressive Mooren's ulcer not responding to conventional therapeutic modalities or as adjuvant in postoperative management of Mooren's ulcer.

References

1. Bowman W (Case 12 p 112) in the parts concerned in the operations of the eye 1849, cited by Nettleship E: Chronic serpiginous ulcer of the cornea. Mooren's ulcer. Trans Ophthalmol Soc UK 22:103-144; 1902.
2. McKenzie H. Diseases of the Eye, Longman. Rees, Orine, Brown & Green London 1854. P. 631.
3. Mooren A: Ulcer Rodens. Ophthalmiatriische Beobachtungen. Berlin. A Hirsehwal, 1867, pp 107-110.
4. Lewallen S, Courtright P. Problems with current concepts of the epidemiology of Mooren's corneal ulcer 41 Ophthalmol 1990; 22:52-5.

5. Wood T, Kaufman H. Mooren's ulcer. *Am J Ophthalmol* 1971; 71:417-22.
6. Schanzlin DJ. Mooren's ulceration. In: Smolin G, Thoft RA, 45. *The cornea*. Boston: Little, Brown, 1987:323.
7. Watson PG. Management of Mooren's ulceration. *Eye* 1997; 11:349-56.
8. Chow CYC, Foster CS. Mooren's ulcer. *Int Ophthalmol Clin* 1996; 36(1):1-13, 1996.
9. Foster CS. Immunotopic Disorders of the conjunctiva, cornea sclera: *Principles & Practice of Ophthalmology*, Second edition. Philadelphia WB Saunders Company, 2000, pp.803-829.
10. Chen J, Eie H, Wang Z et al. Mooren's ulcer in China: a study of clinical characteristics and treatment. *Br J Ophthalmol*. 2000; 1244-1249.
11. Keitzman B. Mooren' ulcer in Nigeria. *Am J Ophthalmol*. 1968;65:679-85.
12. Zhao JC, Jin XY. Immunological analysis and treatment of Mooren's ulcer with cyclosporin A. *Cornea* 1993; 12(6):481-488.
13. Brown SI, Mondino BI, Rabin BS. Autoimmune phenomenon in Mooren's ulcer. *Am J Ophthalmol*. 1976; 82:835-40.
14. Gottsch ID, Liu'SH, Minkovitz IB, et al. Autoimmunity to a cornea-associated stromal antigen in patients with Mooren's ulcer *Invest Ophthalmol. Vis Sci* 1995; 36.1541-7.

Management of Senile Entropion of the Lower Lid

Gauri Nagpal, DNB, Anita Sethi MS, FRCS

Entropion is a common manifestation of the senile lid. When the lid loses tone as a result of aging, there is an in-turning of the margin which is known as senile entropion. The lower lid is usually affected. As a consequence of in-turning of the lid margin, ocular inflammation and tearing may result from contact of the eyelashes or the keratinised epithelium of the eyelid with the ocular surface.

In order to understand the pathophysiology of senile entropion it is essential to review the anatomy of the lower lid.

the orbital fat causes the loss of posterior support and aggravates the condition.

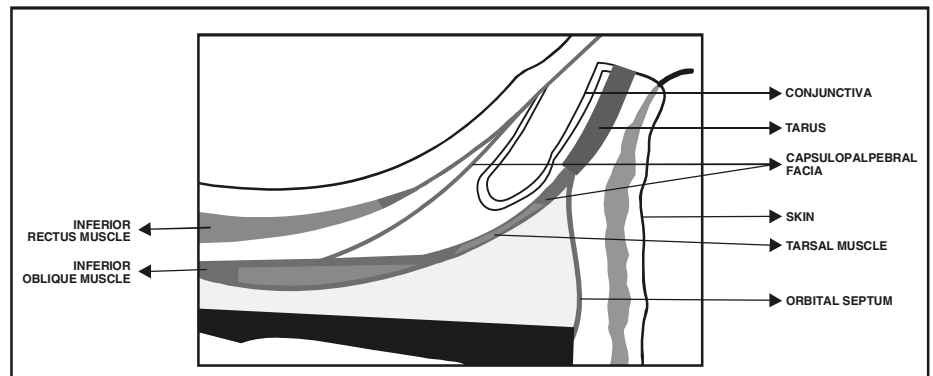


Fig. 1: Surgical Anatomy of Lower Lid

Anatomy of Lower lid (fig.1)

The layers of the lower lid from anterior to posterior are skin, orbicularis (pretarsal and pre-septal), tarsal plate, orbital septum & lower lid retractors and palpebral conjunctiva. The lower lid retractors consist of the inferior tarsal muscle and the capsulopalpebral fascia. The capsulopalpebral fascia of the inferior rectus and inferior oblique is functionally equivalent to the upper lid levator aponeurosis and the inferior tarsal muscle is analogous to the Mullers muscle, together they form the retractors of the lower lid.

Pathophysiology

In involutional entropion, there is laxity of the aging lid structures causing the following changes:

1. Dehiscence/detachment of the inferior lid retractors: stretching and dehiscence or detachment of the capsulopalpebral fascia and mullers muscle causes the lid margin to turn in there by causing vertical elongation of the lid (fig. 3a&b).
2. Horizontal elongation is due to laxity of the tarsal tissues (medial & more importantly lateral canthal tendons)
3. There is overriding of the preseptal orbicularis over the pretarsal orbicularis due to loss of preseptal adherence to the orbital septum. Atrophic changes in

Clinical features (fig.2)

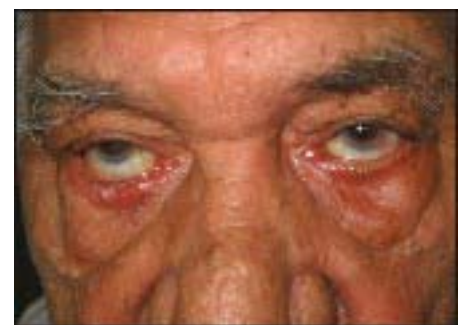The lashes and skin of the lower lid contact and irritate the cornea causing watering.

Vertical laxity or dehiscence of retractors can be clinically seen by

- a) attenuation of the lower lid crease
- b) diminished lower lid excursion in down gaze, normally it is 4mm or more
- c) when the retractors are disinserted they may be visible through the conjunctiva as a gray area several mm below the inferior tarsal border.

Horizontal lid laxity can be judged clinically by a

- a) medially displaced lateral canthal angle which in normal cases is usually less than 5mm from the lateral orbital rim
- b) Snapback test - if the lid is pulled away from the globe, a lid with normal tone quickly snaps back to its normal position and can be distracted no more than 6mm from the globe.



- c) Lateral traction of the lid should not distract the punctum

Fig. 2: Right Lower lid entropion with lid laxity.

Department of Ophthalmology

Sir Ganga Ram Hospital,
Rajender Nagar, New Delhi-60

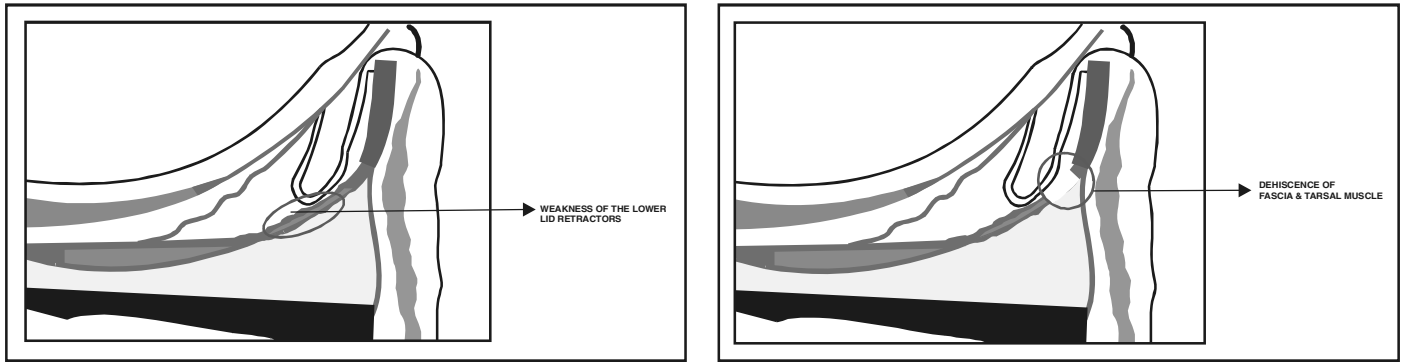


Fig. 3 (a)&(b): Patho Physiology of Senile entropion.

temporally more than 3mm when the medial canthal tendon is intact.

Management of senile entropion

There is not much role of medical management in senile entropion, the definitive management is surgical. Medical management is limited to ensuring lubrication of the ocular surface and treatment of infection.

As a temporary measure for bedridden and for those who have a risk of undergoing surgery, Quickerts sutures or full thickness eversion sutures can be given under local anaesthesia. Double armed 4-0 or 5-0 chromic gut sutures are passed through conjunctiva of inferior fornix, lowerlid retractors are engaged and then exit is made through the eyelid 2-3 mm inferior to the cilia. 2-3 of such sutures are placed in each eyelid.

Permanent treatment of involuntional entropion by surgery is based on following principles:-

- (i) Strengthening the lid retractors as in Jones, Reeh and Wobigs procedure and Modified Jones procedure where the inferior lid retractors are plicated or attached to the tarsus.
- (ii) Shortening the anterior lamina by suturing the preseptal orbicularis to pretarsal orbicularis so as to prevent the migration of orbicularis, forming a cicatrix between the two parts of orbicularis.
- (iii) Removal of the horizontal lid laxity, if present by tarsal strip procedure where a small strip of

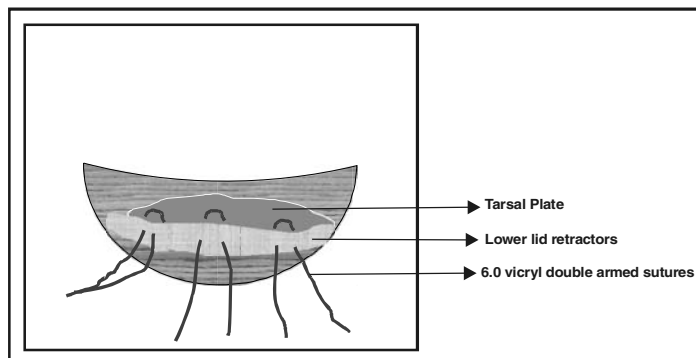


Fig. 4: Passing the sutures to re-attach the lower lid retractors to the tarsal.

lid margin, conjunctiva and skin are removed to create a free end of the tarsal plate that functions as the canthal ligament accompanied by lateral canthotomy and cantholysis or a Bicks procedure which aims at full thickness lid shortening.

A step by step approach to Modified Jones procedures is as follows:-

- ♦ Anaesthesia: The procedure is preferably done under local infiltrative anaesthesia as these patients are usually elderly. Local infiltration with Lignocaine with Adrenaline helps in maintaining hemostasis.
- ♦ Incision marking: Mark a sub-ciliary incision along the length of the lid before infiltration. If there is lengthening, the amount of shortening required should be marked as well.
- ♦ Incision is made into the skin-muscle upto the tarsal plate. The tarsal plate is exposed.
- ♦ Blunt dissection is continued at the inferior margin of the tarsus. The stretched or dehisced retractors will be visible. This can be confirmed by holding the tissue and asking the patient to look up. A small tug will be felt.

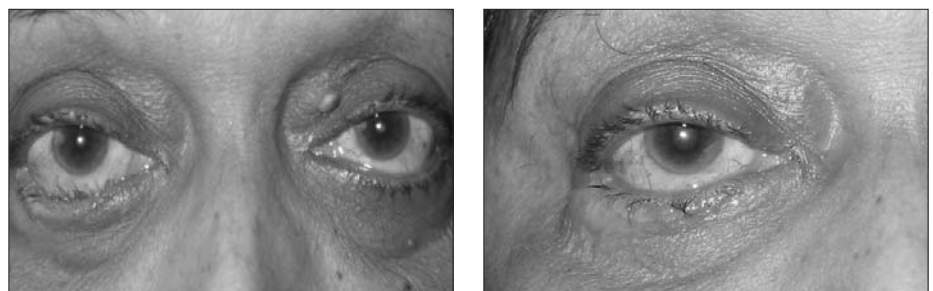


Fig. 5(a&b): Pre-op & post-op pictures of the patient showing senile entropion (5a) and correction of the entropion by Modified Jones Procedure (5b).

- ♦ The retractors now need to be re-attached/plicated and attached to the tarsal plate. Three double armed 6-0 Vicryl sutures are passed to ensure correction along the whole length. The retractors may be plicated and attached or simply reattached, depending on the amount of laxity (fig 4). The three sutures are tightened and the correction observed. The straightening of the margin is immediately seen. One should aim for optimal correction as there is not much change post-operatively. The end-point is when the posterior margin is just apposed to the globe.
- ♦ The skin muscle lamina usually needs to be shortened as well and is excised in a spindle shape.
- ♦ Associated lengthening can also be tackled if required, either by excising the lid in a full thickness pentagonal shape (Bicks procedure), or performing a lateral Tarsal Strip procedure.
- ♦ The incision is closed with 6-0 silk sutures which are removed in 6-7days. Lid margin sutures, if any, are removed after 10-12 days.

Suggested reading

1. Orbit and Oculoplastics Textbook of Ophthalmology Richard R. Tenzel, MD Vol.4, 1993; 3.1-3.12.
2. Atlas of Ophthalmic Surgery Vol. 1. Charles K. Beyer-Machule and Gunter K. Von Noorden. First Indian Edition, 1990; 1.6-1.14.
3. Albert and Jacobiec Principles & Practice of Ophthalmology Vol.4. 2000; 3491-3492.

Silicone Oil Removal: The way I do it

Vinay Garodia MD, DNB, MNAMS, FRCS

Silicone oil is commonly used in the management of complicated retinal detachments and has helped significantly in improving the results. As is true with any of the useful tools, even silicone oil has its own set of complications like cataract, glaucoma, keratopathy etc. Owing to these long term complications of intravitreal silicone oil, its removal is recommended after a certain period of tamponade. On average we prefer to remove the silicone oil 3 months after the vitrectomy surgery, provided the retina is flat and there is no active traction. This article would describe the technique followed by us for silicone oil removal.¹

For silicone oil removal, infusion of balanced saline solution is made into the vitreous cavity and the silicone oil is either allowed to flow out passively^{2,3} through a sclerotomy port or is removed by active suction.⁴⁻⁶ The passive removal not only takes more time but also involves enlarging the sclerotomy port to 3 mm or more,² and hence frequently leads to diffuse vitreous hemorrhage.³ For generating active suction, expensive instruments such as viscous extractors have been devised. A few inexpensive methods such as use of syringe suction^{4,5} and anesthetic apparatus⁶ have also been described, but both these methods fail to provide a precise linear control of suction. We have described a simple, inexpensive, safer method for silicone oil removal¹ using a 19-gauge needle and the active suction of the regular vitrectomy machine, maintaining good control, without the need of expensive attachments such as viscous extractors.

Surgical Technique

After placement of a regular 20-gauge infusion cannula inferotemporally in the pars plana area, another sclerotomy is made with the MVR blade (20 G) and enlarged slightly to allow the passage of a 19-gauge needle. This sclerotomy is made superiorly at 12 o'clock position if only silicone oil removal is planned, and is made at 10 o'clock position if additional intravitreal procedures such as endolaser treatment or membrane peeling are also contemplated. Even for aphakic eyes, instead of removing silicone oil through the limbal incision, we prefer to make sclerotomy ports at the pars plana area, so as to decrease the chance of any possible endothelial injury due to

turbulence of the fluid and the silicone oil in the anterior chamber. A regular hypodermic 19-gauge needle is attached to one end of the regular IV set (Figures 1 and 2). As shown in Figure 1, the other end of this IV set tubing is attached to the suction cassette of the vitrectomy machine. This tubing fits snugly inside the opening in the suction cassette of the Storz vitrectomy machine (Bausch and Lomb, Rochester) without the need of a connector (Figure 1). For other vitrectomy machines, a simple connector attachment, available with the tubing of the vitrectomy probe, can be used to connect this IV set tubing with the suction cassette. This tubing of the IV set is preferred, as it is easily available, disposable, inexpensive, and has a reasonably wide bore to minimize the resistance. The vitrectomy machine, with the cutter switched off, provides the suction for silicone oil removal. The main bulk of the silicone oil removal is done using a preset suction of 400 mmHg with the 19-gauge needle placed in the anterior vitreous cavity. The surgeon, with the help of the machine's foot pedal, has a precise linear control over the actual suction. Toward the end of the procedure, the posterior surface of the silicone oil bubble becomes visible as a meniscus. The residual bubble is followed with the tip of the needle, taking care to keep the needle tip in the center of the pupil and always under visualization, so as to prevent any possible injury with the pointed tip. This is the time when one also needs to be careful to keep the tip of the needle within the silicone oil bubble to prevent the collapse of globe. By now, there is a significant amount of silicone oil present in the tubing of IV set. This silicone oil in the tubing provides some resistance, and thus acts as a buffer against the surge and a sudden collapse of globe, in case the needle tip with high suction is temporarily outside the silicone oil bubble. In contrast, even the expensive viscous extractors do not have this advantage of preventing surge, as the needle directly drains into a syringe without any intervening tubing.

After removing the bulk of silicone oil, the preset suction of the machine is reduced to 200 mmHg, and the 19-gauge needle is replaced by a 22-gauge cannula (Figures 1 and 2). The smaller opening of the cannula prevents the sudden collapse of globe at this stage when the vitreous cavity is predominantly filled with saline. Moreover, as this cannula has a bent and smooth end, it may be used through the same sclerotomy port to remove the few small droplets of silicone oil in anterior chamber in an aphakic eye, taking care not to touch and damage the endothelium. The last few small bubbles are allowed to passively flow out of the eye through the sclerotomy port and are not actively sucked to prevent aspiration of the residual

Vitreous Retina Consultant

Visitech Eye Centre and Hospital
New Delhi

vitreous in the periphery and inadvertent damage to the retina and choroid with the needle or cannula.

In cases where an additional intravitreal procedure is planned, one more sclerotomy port can be made for a light pipe. However, the earlier sclerotomy port that had been enlarged to accommodate the 19-gauge needle has to be made smaller by placing a suture to prevent leakage of fluids through it. This technique comes in handy especially while removing silicone oil in cases with recurrent retinal detachment. With the accurate control of suction and the prevention of surge using this technique, it can be ensured that the detached retina does not get sucked into the needle tip inadvertently. Most of the vitrectomy machines also have a reflux mechanism, which can be used to free the retina in the unlikely scenario of retina getting sucked into the needle tip. Even if the reflux is not available in the machine, one can immediately stop the suction by lifting the foot off the pedal and then simply pinch the tubing to generate the reflux.

Comments

We have been using this method for silicone oil removal with various vitrectomy machines made by Storz (Bausch and Lomb), MIDLAB (San Leandro, CA), and DORC (Kingston), and in our experience, this technique works very well with all these machines. Using this technique in more than 100 eyes, we have never faced any perioperative complications. This technique is reasonably fast and takes an average of 4 to 5 minutes to remove the bulk of silicone oil from the vitreous cavity. It is very difficult to remove the residual small silicone oil bubbles. After converting

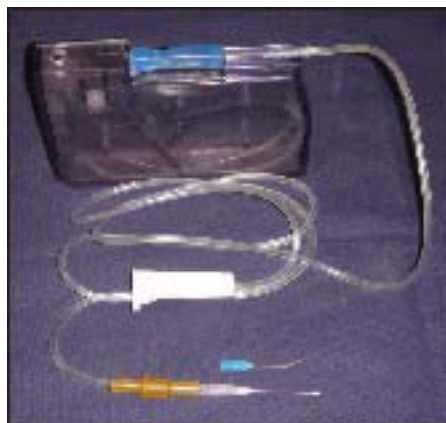

Fig.1: The assembly used for removal of silicone oil. The tubing for intravenous infusion (IV set) is used. One end of this IV set tubing (after cutting the tube so as to remove the fluid chamber of the IV set) is inserted directly into the slot of the suction cassette of the vitrectomy machine (Storz Premier Microsurgical Systems). At the other end of the tubing either the 19-gauge needle (below) or the 22-gauge cannula (above) can be attached, as explained in Fig. 2.

into three ports, as described earlier, fluid-gas exchange may be performed to remove these small droplets or foam from the surface of retina using a soft-tipped flute needle.^{5,6}

The earlier described methods using a syringe suction^{4,5} or anesthesia suction machine⁶ do not provide a linear control of suction. Moreover, in these methods, to stop the suction the tubing has to be clamped, which requires the second hand of the surgeon, thus leaving only one hand for controlling the intraocular instrument. Alternatively, if an assistant is asked to clamp the tubing, there has to be an inevitable lag time between the surgeon's request and assistant's action, thus making the procedure more prone to potential complications. However, with this

new and simple technique, the surgeon can very efficiently and effortlessly control the suction in a linear manner by using the machine's foot pedal control. This whole system of removing silicone oil is very easy to assemble. It does not require any additional instruments or equipment, as it utilizes the already available vitrectomy machine. As the tubing used is totally disposable, there is no problem of wear and tear in the tubing leading to loss of suction. The total cost of the disposable items needed for this technique—i.e., 19-gauge needle, 22-gauge cannula, and the IV set tubing—costs less than Rs. 45.00 (approximately equivalent to \$1.00) in India. Hence this new technique for silicone oil removal is not only inexpensive, but is also convenient, safe, and reasonably fast. We recommend this technique for routine use in all cases of silicone oil removal with or without additional intravitreal procedures in aphakic, phakic, and pseudophakic eyes.

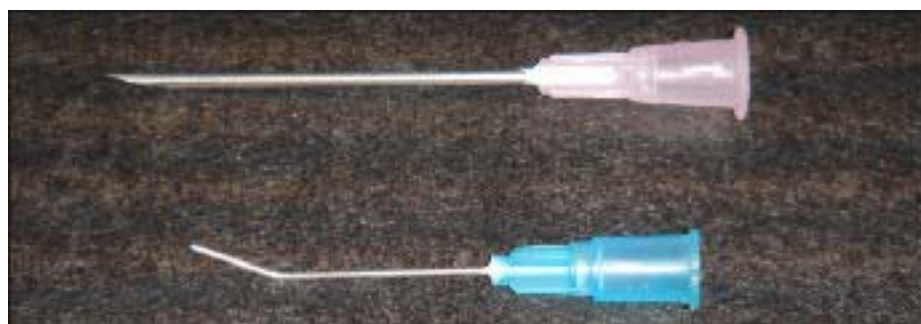

Fig.2: Magnified view of the 19-gauge needle (above) and the bent 22-gauge cannula (below). The 19-gauge needle is used to rapidly remove the main bulk of the silicone oil, and the bent 22-gauge cannula with a smooth tip is used during the later stages of surgery to remove the residual small silicone oil bubbles, especially from the anterior chamber of aphakic eyes.

References

1. Garodia VK, Kulkarni A. Silicone oil removal using vitrectomy machine: A simple and safe technique. *Retina* 2001;21:685-687.
2. Casswell AG, Gregor ZJ. Silicone oil removal. I. The effect on the complications of silicone oil. *Br J Ophthalmol* 1987;71:893-897.
3. Casswell AG, Gregor ZJ. Silicone oil removal. II. Operative and postoperative complications. *Br J Ophthalmol* 1987;71:898-902.
4. Gopal L, Mehta S. Silicone oil removal: a simple technique. *Retina* 1997;17:266-267.
5. Bassat IB, Desatnik H, Alhalel A, et al. Reduced rate of retinal detachment following silicone oil removal. *Retina* 2000;20:597-603.
6. Immonen I, Vuorinen R, Tommila P. A simple and inexpensive system for the removal of silicone oil through a 20-gauge opening. *Retina* 1995;15:263-264.

Incisions in Phaco – Complications and Management

Piyush Kapur, DNB, MNAMS, Harbansh Lal, MS, Anita Sethi, MD, FRCS

An incision of 3-3.5mm at the limbus results in minimal astigmatism of 0.25-0.5D and for all practical purposes is considered astigmatically neutral.

Incision forms the first basic and most important step for a successful completion of good phacoemulsification. The main characters of a good incision are:-

- (i) It should be self sealing
- (ii) Non-leaky/not very tight
- (iii) Long enough to ensure a secure wound closure, and astigmatically neutral

A good valve action of the incision forms the basis of a good suture-less surgery. The incisions commonly used in phacoemulsification are.

- ♦ Side port incision
- ♦ Scleral tunnel
- ♦ Clear corneal incisions

Side port incision

- ♦ Generally made on the left side of the main incision.
- ♦ A location between 2-3 clock hours from the main port is ideal for this purpose.
- ♦ It should be 1 to 1.5mm, clear corneal.
- ♦ A square tunnel is preferable.

Common problems/complications encountered:-

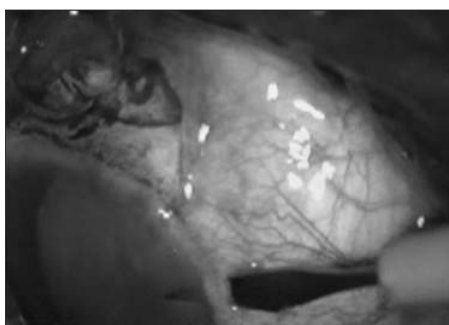


Fig. 1: Note a more posteriorly made side port incision

1. **Scleral Location** – accidentally made -a more scleral port

- Cause – more posterior location
- Complications encountered:-

Department of Ophthalmology

Sir Ganga Ram Hospital, Rajender Nagar, New Delhi

- ♦ A more scleral port bleeds more.
- ♦ Increases the incidence of iris prolapses.
- ♦ Scleral tissue retracts and thus increasing the incidence of wound leak.

- Management – a leaky non sealing side port may require to be sutured in the end.

2. Use of Excess force while entering

➤ *Cause* – use of a blunt instrument may require excess force, which leads to a sudden entry. These can rupture the anterior capsule or lead to a ragged side port.

➤ *Prevention* – using a sharp instrument

➤ *Management* –

- ♦ In case there has been an inadvertent capsular tear, analyse the tear on the capsule. If there is difficulty in recognition, stain the capsule. Make a capsulorhexis large enough to include the tear within the CCC margin itself.
- ♦ If the side port is ragged, you can make an other side port

Scleral tunnel

An ideal tunnel is one with a minimum width of 3mm in the center and flares out at the periphery. A 1.75mm corneal lip is maintained all along the incision parallel to the limbus. A depth of 1/3 to 1/2 thickness of sclera is ideal (300 to 500m)

The common problems encountered in constructing a scleral tunnel are:-




Fig. 2: Scleral disinsertion. Note the gape at the external wound because of the deep initial cut.

(i) **Scleral dis insertion :-**

Cause

This occurs if the initial cut is more than 80% to 90%

deep. This results in wound gape and astigmatism.

Prevention:- Gentle pressure after assessing the depth at the initiation of the incision is the main key for prevention of such a complication.

Management:- After carefully estimating the depth; the tunnel construction should be initiated at 1/3 to 1/2 the depth; rather than initiating from the base of the initial cut.

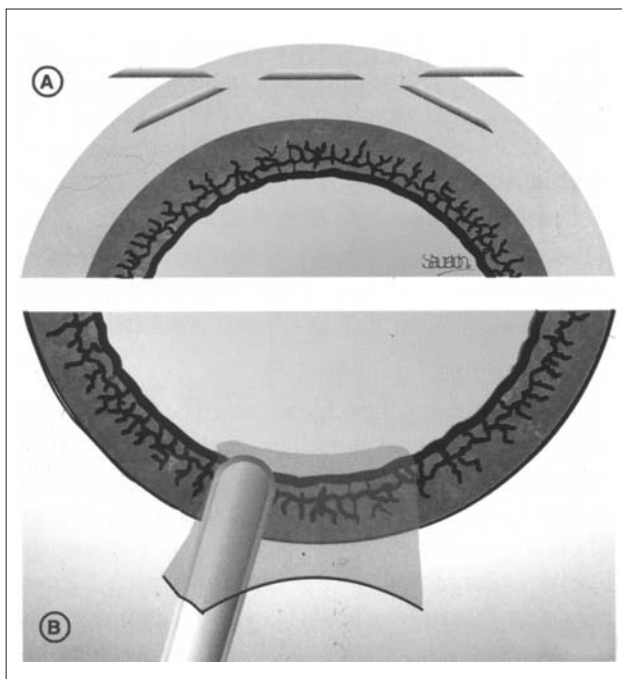


Fig. 3: (A) Note the direction of blade. If it is parallel to the floor, it will cut the edges. The blade must dip on the side to avoid cutting the edges. (B) Torn edges due to not following the curvature of the globe.

(ii) **Torn edges:-** one can experience a torn edge at any stage of the surgery. It may be while construction of the wound; during surgery or while enlarging the incision for IOL insertion. With a torn edge the incision loses its self sealing capacity and may lead to a leaking wound.

Prevention:- Such a complication can be prevented by maintaining the movement of the knife along the curvature of the globe. The knife has to be tilted little towards the side of the motion of the blade, rather than just pushing it straight in. This helps to maintain adequate depth on the edges as well.

During enlargement the surgeon tends to lift one flap up and in the process ends up with cut edges. This can be prevented by pressing to the keratome against the globe (to flatten the curvature) and pointing the lip up wards.

Holding the flap with a toothed forceps may also cause a tear in the flap.

Management:- Managing a torn edge depends on the

wound integrity. If the tunnel is long and the internal lip is secure, It will not leak and surgery is comfortable. But if the tunnel is not long enough & the tear is large, it may leak. In such a situation it is better to suture the torn edge and then proceed.

(iii) **Premature entry:-**

Early perforation of the cornea results in a premature entry into the AC. The smaller corneal lip thus produced will not have an efficient valvular function resulting in an unstable chamber and repeated iris proplase.

Cause:- Premature entry can be due to a number of reasons. The initial groove may have been too-deep thus leading to a deeper plane of dissection. Too sharp a knife may also result in an uncontrolled entry. One of the common cause of a premature entry is the failure to move the knife in accordance with the curvature of the corneal dome.




Fig.4: Premature entry. Advancing the knife parallel to the floor (not following the curvature of the corneal) leads to premature entry.

Management:- If the initial groove is too deep and you have started dissecting in a deep plane and you have recognized this in time, you can try to come to a more superficial plane. This may be facilitated with the use of a bevel up knife. Alternatively, one can make another groove 1 mm in front of the initial incision and repeat dissection in a more superficial plane. To prevent premature entry due to incorrect advancement of the knife, the tip should be pointed slightly towards the ceiling rather than the floor while advancing.

If the premature corneal entry has already been made, the further course taken depends upon the type of cataract and degree of mydriasis. In case of soft cataract, with fully dilated pupil and no iris prolapse, one may proceed with the surgery as planned. If the pupil is not well dilated or there is repeated iris proplase or the cataract is hard then the surgery will have to be modified. If the initial tunnel is made at 12 O'clock, one can suture the initial incision and complete the nucleotomy from a clear corneal temporal incision. The original 12 O'clock tunnel can be used for lens insertion. After IOL insertion inflate the globe with air, constrict the pupil and if required suture the wound.

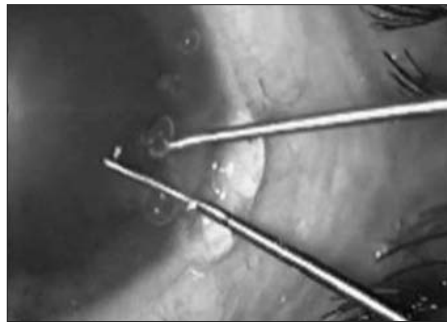



Fig. 5(a) : Note the incision beginning in a superficial plane. **(b)**: Managing a thin flap by making and other incision in a deeper plane after recognising a thin flap before perforation.

(iv) Thin flap

Cause:- A shallow initial groove is the commonest cause of thin flap. Too sharp or too blunt a knife may cause the same problem. A blunt knife used ends up tearing the flap instead of cutting it; resulting in a thin and shredded flap and at times even a button holing may result. These thin flap are predisposed to develop a torn edge and are also liable to develop corneal burns leading to a leaking wound with unstable chamber and unsafe surgery.

Management:- If a thin flap is detected early i.e. before perforating the AC, stop and make a fresh start. Make another groove 1mm behind the initial incision and proceed in a deeper plane to achieve an adequately deep flap with a long tunnel.

If the whole tunnel is completed and the cataract is soft one can proceed with the surgery in one normal way utilizing minimum energy and taking all precautions to avoid a corneal burn. In case of a harder cataract it is better to make a fresh start using another site.

Clear Corneal Incision

With the advent of foldable IOLs the size of the incision has further decreased making it possible to make a self sealing corneal incision. The temporal approach is specially suited for a clear corneal incision, since horizontal diameter the of cornea is usually 1 mm more than the vertical and the tunnel interferes less with the visibility. The incision must have a good valve action, it should be astigmatically

neutral and it should be tight enough to provide a good stable chamber. At the same time too tight incision can lead to a wound burn. So the calibration and judgement should be appropriate. Some common problems encountered in constructing a clear corneal incision are:-

(i) Torn edges:- This is more commonly seen with clear corneal incisions particularly during

enlargement.

Cause:- This is due to failure to understand the curvature of the cornea. While advancing the knife, the beginners tend to lift up the flap and concentrate on the tip of the knife. In such a situation the shoulder of the knife may cut the edges of the external wound.

Prevention:- During entry one should press the shoulder of the knife downwards against the floor of the tunnel and point the knife slightly upwards. Once the shoulder has passed the external wound concentrate on the internal wound enlargement.

Management:- Same as that for scleral tunnel.

(ii) Premature entry:-

Cause:-

- Common with a very sharp knives
- Occures more commonly with uniplanar incisions.
- Making a deep initial groove in biplanar and triplanar incisions.

Prevention and Management:- Same as that for scleral tunnel.

(iii) Long tunnel:- Though a longer tunnel gives a good valve action, and thus a stable chamber, at the same time too long a tunnel can also be hazardous. A long tunnel can cause more distortion of the cornea; and poor visibility which makes the surgery more difficult.

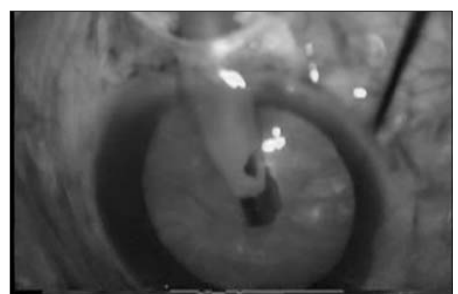
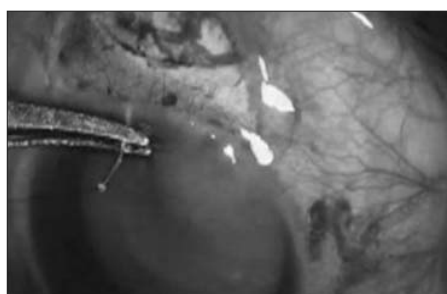
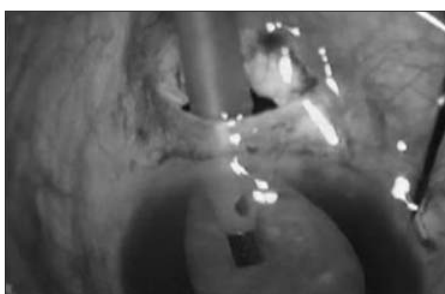

Fig. 6(a) Iris prolapse in a leaking wound. **(b)**: Suturing a leaking tunnel note that the suture must pass through both the superficial and deep flaps to give a secure non-leaking stable chamber. **(c)**: Note stable chamber after suturing the tunnel without any iris prolapse.




Fig. 7(a): Wound burn with fish mouthing

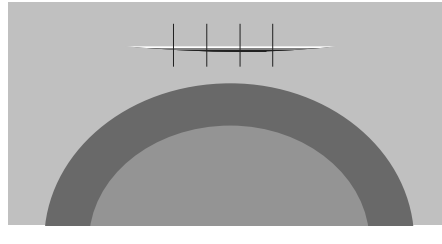


Fig. 7(b): Radial sutures-induce more astigmatism

Causes:- It is more common in soft eyes where the AC is not firm enough to facilitate the smooth movement of the knife. It is difficult to penetrate the cornea in soft eyes. In myopic eyes a smaller tunnel is preferable to prevent distortion of the cornea during the surgery.

Prevention:- Always construct the tunnel in a tense eye ball, and tend to perforate the cornea a little early (in myopic eyes) keeping in mind that one may normally end up making a longer tunnel.

(iv) Leaky wound

Cause:-

- (i) wider tunnel =>3mm

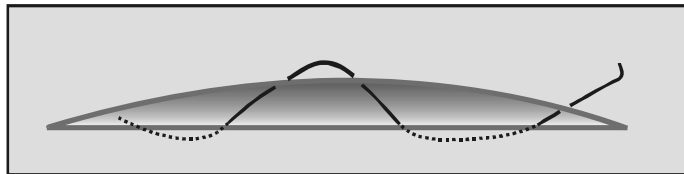


Fig. 8(a): Passing the horizontal suture from the anterior as well as the posterior lip.

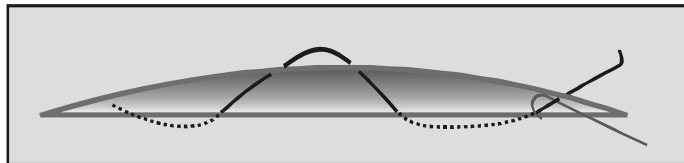


Fig. 8(b): Hooking & Pulling out the suture from the first bite.

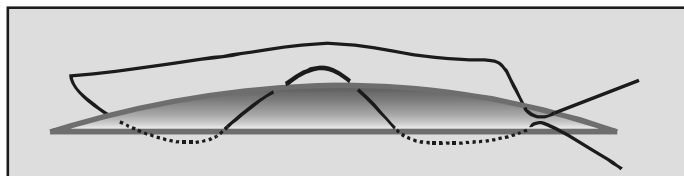


Fig. 8(c): Completing all the bites & tying the knot after tightening the sutures.

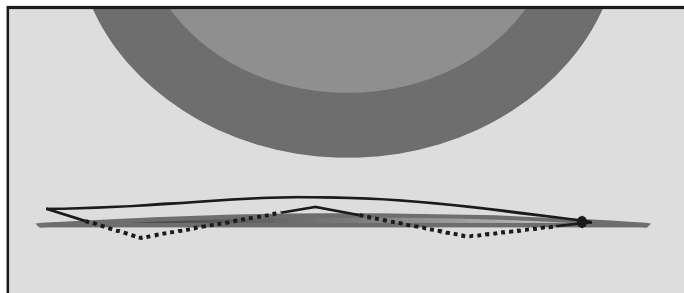


Fig. 8(d): Tying the knot to achieve a well apposed wound.

(ii) premature entry

(iii) wound burn.

A leaky wound can be very unstable and make the surgery very difficult with iris prolapse and fluttering posterior capsule.

Management:-

If AC is not too unstable, cataract is not too hard and pupil well dilated; one can proceed with phaco from the same port. In the event of difficulty, one can tighten the wound by placing one interrupted suture at one end of the tunnel. The suture has to be such that it should pass through both the superficial and deep flaps to achieve a proper tunnel closure, which is tight enough to prevent any iris prolapse.

(v) Descemet's detachment

Cause:- This can occur at any step especially if the incision is ragged. Inserting the phaco probe with the fluid on through a tight wound is a common cause. If needs to be recognised and distinguished from floating capsule pieces. The detached descemet's can be unrolled and repositioned with visco-clastic and air injected to keep it in place.

(vi) Wound burn

Cause:- Thermal insult of the anterior lip of the incision. This leads to retraction of the anterior lip causing fish mounting of the external lip of the incision. These incisions have to be sutured to maintain the wound integrity. Suturing this wound gape would involve passing an infinity suture which passes horizontally.

Horizontal suture gives minimum astigmatism and a good wound apposition. Never pass radial sutures on this retracted lip, as radial suture tend to pull the anterior lip causing very significant post-operative astigmatism.

Horizontal Suture

- ◆ This suture is tied in such a way that it causes minimal astigmatism by apposing the anterior and posterior lip.
- ◆ The suture bite is taken by passing through the normal sclera taking almost 70-80% of sclera thickness (fig. 8a). This bite involves both the anterior and posterior lips.
- ◆ Suture is taken out 2-3mm away from the entry point.
- ◆ 2 bites are taken to attain 2 cross sutures which are then pulled out from the other end of the incision.
- ◆ The suture at the first bite is then hooked & pulled out from the inner mouth (fig 8b).
- ◆ The last bite involves only the anterior lip near the entry point to finally attain two threads lying at one end (fig. 8c).
- ◆ Lastly the sutures are tightened and knot is tied to attain a well apposed wound (fig 8d).

Functional Acuity Contrast Chart (F.A.C.T Chart)

Zia Chaudhuri, MS, MNAMS, FRCS, A.K. Grover, MD, MNAMS, FRCS, Shaloo Bageja, DNB

The FACT Chart, developed by Dr Arthur P Ginsburg,¹⁻³ a pioneer of Contrast Sensitivity Technology, offers a sensitive and comprehensive measure of functional vision than does standard Snellen visual acuity. The standard Snellen acuity tests the ability to identify progressively smaller, high contrast letters. Actual vision in real-world situations is not always a high contrast black and white situation. It consists of objects having a wide range of sizes viewed under a variety of visually degrading conditions like fog, bright sun, night hours etc. Many visual disorders show more significant vision loss under such illumination than when tested under the high contrast viewing of Snellen's visual acuity charts.

The FACT effectively evaluates the patient's vision over a range of size and contrast, which closely simulates the normal environment. Thus it often picks up early vision loss due to a wide variety of eye disease and visual pathway disorders such as cataract, glaucoma, macular and retinal dysfunctions, optic nerve disease, which may be missed on examination by standard Snellen's visual acuity charts.

The FACT system includes

1. A standard 37 inch x 27 inch framed distance chart (Figure 1)
2. A Near Chart with Calibrated Holder (Figure 2)
3. A Light Meter to record the required illumination for the test to take place (when the standard test can take place) – (Figure 3, 4)
4. Record Forms – (Figure 5)
5. Colour pens

The chart comprises of progressive high quality sine-wave grating size changes in steps equal to one octave i.e. a factor of two between rows A, B, C and D and half octave between rows D and E. The corresponding spatial frequencies are 1.5, 3, 6, 12 and 18 cycles per degree (cpd). The contrast step between each grating patch is 0.15 log units. This means that there is a 50 % loss or a 100 % gain in contrast for any two contrast step increase or decrease, respectively. The contrast ranges in this chart exceeds the normal population range of contrast sensitivity, so that all kinds of abnormalities can be effectively charted.³ The

gratings are tapered into an average gray background to eliminate ghost images and to keep the mean retinal illumination constant. The grating patch size, 1.7 degrees, exceeds the size of the macula (1-5°) and the gratings are tilted at a degree of +15°, 0° and -15°, to keep them within the orientation bandwidth of the visual channels.¹

Use of the FACT Chart

Distance Chart

- A. Mounting of the Chart (Distance test) – Figure 1:
 - a. Distance of 10 feet (3 meters) is required
 - b. The wall on which the FACT Chart is to be mounted should be glare and shadow free.
 - c. The bottom of the chart should be approximately 4 feet from the floor.
 - d. The chart can be mounted on the notched hanger supplied.
- B. Calibration of light for the FACT Chart
 - a. The FACT will accurately measure contrast sensitivity under the normal office lighting 20-70 foot-lamberts (68 – 240 cd / m²) indicated by the green area on the lightmeter. A mark has also been placed on the meter at the 25 foot-Lambert (85 cd / m²) position.
 - b. A lightmeter (Figure 3) is included with the FACT chart to ensure test reproducibility and accuracy. The lightmeter is held 2 inches from each of the 4 corners of the chart. The red needle on the lightmeter in the green area indicates adequate illumination while if the lightmeter is not in the green area, the illumination would have to be increased or decreased accordingly.
 - c. It is extremely important to calibrate the charts for the appropriate interpretations of the test.

Near Chart

- A. Use of the calibrated holder
 - a. The chart is placed at the 18 inches distance position or at the test distance for the patient's bifocals. The patient places the chin rest against his chin. If the patient wears bifocals, the reading portion of their lenses is used for assessment (Figure 2).
- B. Calibration of light for the FACT Chart
 - a. The FACT Chart accurately measures contrast sensitivity under normal lighting of 20-70 foot-Lamberts (68 – 240 cd / m²) as has already been described for the Distance Chart.

Department of Ophthalmology,

Sir Ganga Ram Hospital,
New Delhi

than one contrast value (patch) at 2 or more adjacent frequencies.

Interpretations

- ♦ Severe vision loss causes degradation of the entire contrast sensitivity curve.
- ♦ Losses in the high frequencies usually indicate problems with the macula, and refractive errors
- ♦ A curve with normal high frequency contrast sensitivity and abnormal low and/or mid-frequency contrast sensitivity indicates the possibility of a neurologic problem.

Clinical Applications

The FACT charts are designed to help identify vision loss from a variety of disorders, many of which are not detected by high or low contrast Snellen Acuity tests. Many conditions, which hinder the ability to recognize low contrast objects, while having limited impact on the ability to differentiate high contrast objects, can be identified by this method. Some of the clinical applications of this technique are:

1. **Refractive Errors and Refractive Surgeries:** ⁴⁻⁶ These disorders initially manifest as a decline in contrast sensitivity first at smaller grating sizes and then subsequently at higher spatial frequencies. As the degree of refractive error increases, the contrast declines at the middle and then at the larger grating size. Post-refractive surgery, the curves simulate the current refractive status of the eye. For ex, if the patient was a high myope who remains under-corrected at the end of a refractive surgery, the contrast curves simulate the curves for mild to moderate myopia. An interesting observation in a few studies was that the contrast sensitivity improvement was significantly larger in the wave-front guided LASIK for all spatial frequencies than with standard LASIK.
2. **Contact Lenses:** Contrast sensitivity assessment is useful when determining appropriate contact lens fit and also to assess when a replacement is required. Uncorrected residual astigmatism from a soft contact lens can result in decreased contrast sensitivity at higher spatial frequencies when compared to hard lenses. Significant contact lens

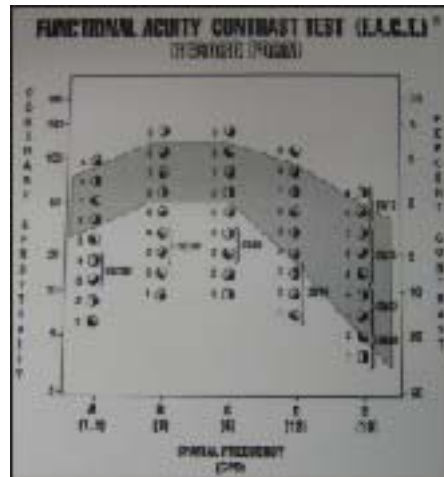


Fig. 5: Record Form (Central gray area denotes area of "normality")

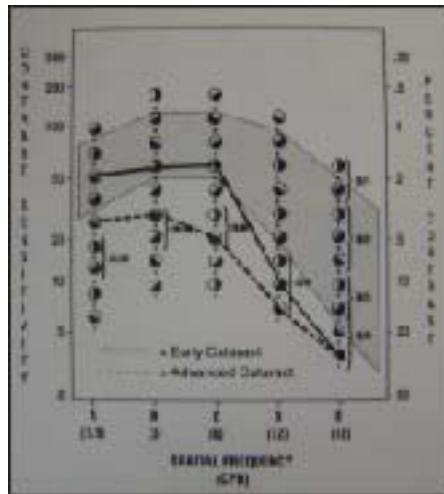


Fig. 6: An example of the contrast curve in a patient with bilateral cataract, more severe in the left eye (RE BCVA is 20/40 and LE BCVA is 20 / 100)

deposits can result in decreased contrast sensitivity at the middle and higher spatial frequencies. This may be used an indication for the replacement of the lenses.

3. **Amblyopia:** ⁷ Visual loss due to amblyopia can be identified when the curve from the amblyopic eye are compared to its fellow eye. The amblyopic eye has lower contrasts for all grating sizes than the fellow eye. This has been seen with both anisometric and strabismic amblyopia. Bilateral amblyopes have decreased contrasts for all grating sizes in both eyes vis-à-vis normals for the same age and gender.

4. **Optic Neuropathy:** ⁸⁻¹¹ These entities, occurring as a result of various causes, affects contrast sensitivity over all grating sizes. Multiple sclerosis and neuropathies due to pituitary adenomas usually affects the middle grating sizes. Although, glaucoma is believed to reduce contrast sensitivity over all grating sizes, a few studies have shown reduced contrast mostly at the middle spatial frequencies, especially in row C.

5. **Cataract and Pseudophakia** ¹²⁻¹⁸: Early cataracts generally cause contrast sensitivity losses similar to refractive disorders at higher spatial frequencies (rows D and E). Later, the

loss of contrast can spread over the lower as well as middle spatial frequencies. Symptoms of glare exacerbates the results for patients with cataracts, producing a lower contrast sensitivity at some or all grating sizes. Certain studies have correlated the intensity of posterior capsule opacification and contrast sensitivity and found that the co-relation between the change in PCO score and change in CS was highest for row B on the FACT Chart and lowest for row E on the same chart. Similarly, a few studies done on the effect of a particular type of IOL (Multifocal or monofocal) have shown that the contrast functions are affected to a greater extent in patients implanted with multifocal IOLs though the distance and near visual acuity along with the range of accommodation is better in these patients with multifocal IOLs.

6. **Macular Degenerations and Diabetic Retinopathy** ¹⁹⁻²¹: These patients exhibit greater contrast sensitivity loss for all grating sizes with increased degeneration. Similar

changes are seen in patients with diabetic retinopathy, depending on the extent of the changes seen in the retina.

7. **Drugs and Chemicals**²²⁻²³: Exposure to the organic solvents used by workers associated with micro-electronic plants have shown reduced contrast sensitivity in the middle size gratings. Similarly, certain drugs like alcohol and Ibuprofen can also result in loss of contrast over all grating sizes.

“Normal” Functional Vision

A healthy visual system is expected to have contrast functions within the normal range shown by the dotted region on the recording form. This gray area denotes the results expected out of 90 % of the normal population. This curve can be used to compare the shape of the contrast curve outside the normative limits.

There is a normal variation in different individuals while seeing everyday objects. These differences in grating contrast sensitivity within the normal range over different grating sizes can be significant and may affect the visual capabilities of a person who may be considered to be normal. This factor, at times may be of significance especially when one considers professions such as driving and aircraft pilots where decrease in the grating acuity especially in the lower gratings though within the normal range may increase the chances of accidents and crashes.²⁴⁻²⁵

The contrast sensitivity curve can also be interpreted in terms of the Snellen Functional Equivalents. The curve going from the left to the right intersects the brackets in the chart, which gives the approximate vision of the patient in Snellen Equivalent terms.

References

- Ginsburg AP. Spatial Frequency and Contrast Test Chart. US Patent No. 4365873 (December 28, 1982)
- Ginsburg AP. A New Contrast Sensitivity Vision Test Chart. Am J Opt Physiol 1984; 61 (6): 403.
- Ginsburg AP, Evans D, Cannon M, Mulvanny P. Large Sample norms for Contrast Sensitivity. Am J Opt Physiol 1984; 61(2): 80.
- Ginsburg AP, Waring G, Steinberg E. Contrast Sensitivity under photopic conditions in the prospective evaluation of Radial Keratotomy (PERK) Study. J Refractive Corneal Surgery 1990; 6(2): 82.
- Marmor MF, Gawande A. Effect of Visual Blur on Contrast Sensitivity. Ophthalmology 1988;95:139.
- Kaiserman I, Hazarbassanov R, Varssano D, Grinbaum A. Contrast Sensitivity after wave front guided LASIK. Ophthalmology 204; 111(3): 454-457.
- Leguire LE, Rogers GL, Bremmer DL. Functional Amblyopia is a single continuum of Visual Impairment on contrast sensitivity functions. Binoc Vis 1987; 2(4):119.
- Blanchard DL. Contrast Sensitivity: A Useful tool in Glaucoma. Glaucoma 1988; 10: 151.
- Nelson P, Aspinall P, Papasouliots O, Worton B. Quality of life in glaucoma and its relationship with visual functions. J Glaucoma 2003; 12(2): 139-150.
- Regan D, Raymond J, Ginsberg AP, Murray T. Contrast Sensitivity, Visual Acuity and the Discrimination of Snellen Letters in Multiple Sclerosis. Brain 1981; 104: 333
- Balcer LJ, Baier ML, Cohen JA, Kooijmans MF, et al. Contrast letter acuity as a visual component for the Multiple Sclerosis Functional Composite. Neurology 2003; 61(10):1367-73.
- Hess R, Woo G. Vision through cataracts. Invest Ophthalmol Vis Sci 1978; 17: 438
- Ginsburg AP, and Tedesco J. Evaluation of Functional Vision of Cataract and YAG Posterior Capsulotomy Patients using the Vistech Contrast Sensitivity Chart. Invest Ophthalmol Vis Sci 1986; 27 (3): 107.
- Sjostrand J, Abrahamson M, Hard AL. Glare disability as a cause of deterioration of vision in cataract patients. Acta Ophthalmol 1987; 65: 103.
- Ginsburg AP, Osher RP, Blauvelt K, Blosser E. The assessment of contrast and glare sensitivity in patients having cataract. Invest Ophthalmol Vis Sci 1987; 28 (3): 397.
- Buehl W, Sacu S, Findl O. Association between intensity of posterior capsular opacification and contrast sensitivity. Am J Ophthalmol 2005; 140 (5): 927-930.
- Sen HN, Sarikkola AU, Uusitalo RJ, Laatikainen L. Quality of vision after AMO Array Multifocal Intraocular Lens implantation. J Cataract Refract Surgery 2004; 30 (12): 2483-93.
- Pesudovs K, Hazel CA, Doran RM, Elliot DB. The usefulness of Vistech and FACT contrast sensitivity charts for cataract and refractive surgery outcomes research. Br J Ophthalmol 2004; 88: 11-16.
- Lovie-Kitchin J, Fiegl B. Assessment of age-related maculopathy using subjective vision tests. Clin Exp Optom 2005;88(5):292-303.
- Loshin DS, White J. Contrast sensitivity: The Visual Rehabilitation of the patient with macular Degeneration. Arch Ophthalmol 1984; 102: 1303.
- Trick GL, Burde RN, Gordon MO, et al. The relationship between hue discrimination and contrast sensitivity in patients with diabetes mellitus. Ophthalmology 1988; 95(5): 693.
- Ridder WH, and Tomlinson A. Effect of Ibuprofen on contrast sensitivity. Opt and Vis Sci 1992; 69(8): 652.
- Frenette B, Mergler D, Bowler R. Contrast Sensitivity loss in a group of former microelectronics workers with normal visual acuity. Opt and Sci 1991; 68(7): 556
- Oswley C and Sloane ME. Contrast Sensitivity Acuity and perception of “Real World” targets. Br J Ophthalmol 1987;71:791.
- Babizhayev MA. Glare disability and driving safety. Ophthalmic Res 2003; 35(1):19-25.

FOR SALE

SLIT LAMP (USA)

KEROTOMETER (Switzerland)

TESTING BOX

All are in Perfect Working Condition

Contact: Dr. R.L. Pathak

952, Sector-15,

FARIDABAD - 121 007

Tel.: 0129-2281098

Ultrasound Biomicroscopy in Glaucoma

Sushmita Kaushik, Reema Bansal, Rajeev Jain, Amod Gupta

Introduction

The ultrasound biomicroscope (UBM) is a high frequency ultrasound machine (with 50-100 MHz transducers) used to image ocular structures anterior to the pars plana region of the eye (1). It produces cross-sectional images of anterior segment structures providing a lateral resolution of 50 μ m and an axial resolution of 25 μ m with a depth of penetration of approximately 4-5 mm. The field of view is 4 x 4mm and the scan rate is 5 frames/second.

The high-resolution cross-sectional images acquired by the ultrasound biomicroscope are akin to an in vivo histological section (Figure 1).

50-MHz transducer probe (Figure 2).

Image acquisition

After instilling 4% lignocaine in the eye, a plastic eye cap is used to gently part the lids and retain a layer of 2% methylcellulose as the coupling agent. To maintain a steady fixation and constant accommodation, the patient is asked to fix at with the fellow eye on a ceiling target. The probe is manually moved perpendicular to the structure to be scanned (Figure 3).

Clinical Application in Glaucoma

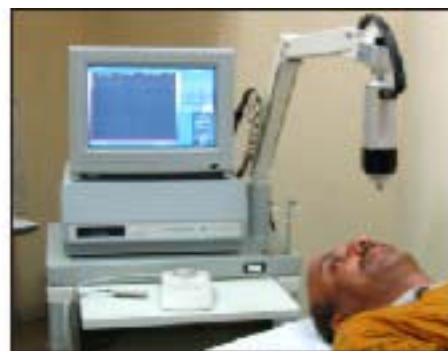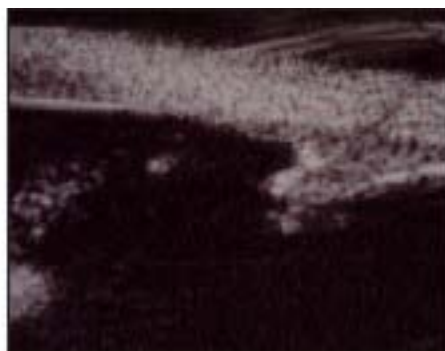
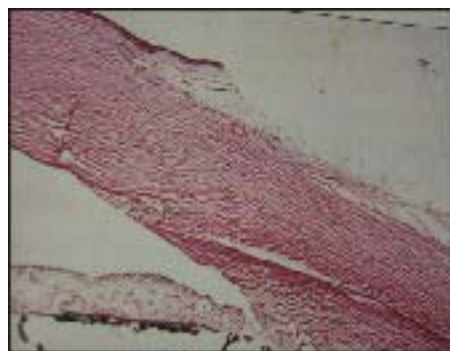


Fig. 1: (Left) Histopathological section of the angle of an eye enucleated for intractable glaucoma following trauma. (The black arrow depicts the area of angle recession). (Right) UBM picture of an eye with traumatic iridodialysis and angle recession, shown by the white arrow.

Fig. 2: The UBM machine

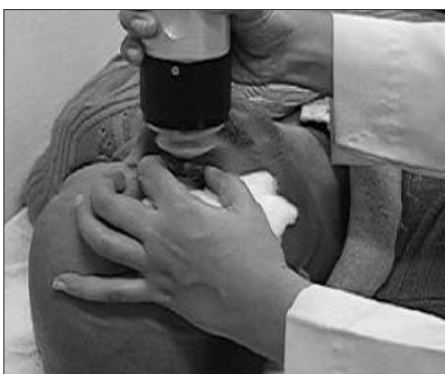

Fig. 3: Image acquisition

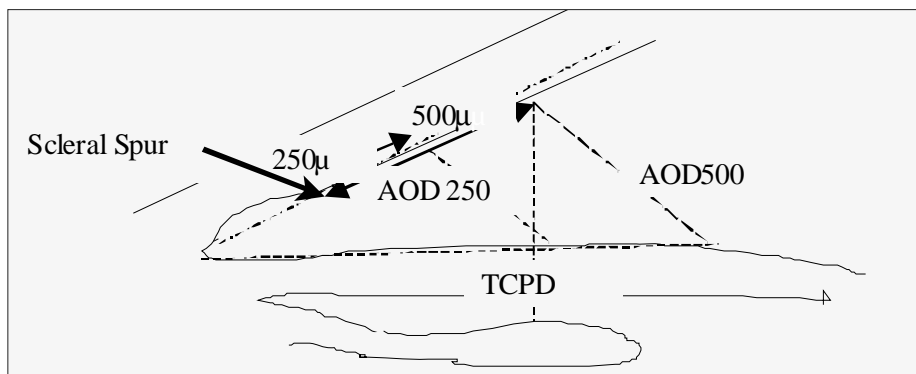


Fig. 4: Angle parameters measured by the UBM

Instrumentation

All UBM images shown here were acquired using the UBM Model 840 (Paradigm Medical Industries, Inc.) with a

The iridocorneal angle, iris, ciliary body and posterior chamber can be imaged in detail and the dimensions and anatomical relationships of these structures determined (2).

Department of Ophthalmology,

Postgraduate Institute of Medical Education and Research,
Chandigarh - 160012

Quantification of anterior chamber angle

UBM permits reproducible imaging of the anterior

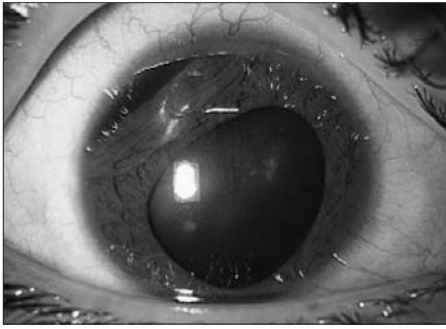


Fig. 5: Anterior segment photograph of an eye showing post-traumatic iridodialysis.

chamber angle (Figure 4) and can determine the state of closure of the angle even when not visualized by gonioscopy (2). Pavlin et al (2) have defined different UBM parameters that characterize the anterior chamber angle. The angle-opening distance (AOD) is defined as the distance from corneal endothelium to anterior iris, perpendicular to a line drawn along the trabecular meshwork at 250m (AOD 250) and 500m (AOD 500) from the scleral spur. TCPD (trabecular meshwork-ciliary process distance) defines the space available between the trabecular meshwork and the ciliary process.

Trauma

This figure illustrates the ability of UBM to define various manifestations of trauma like iridodialysis, cyclodialysis and angle recession.

Pupillary Block

Pupillary block is diagnosed when the iris is bowed forward and the angle appears occludable on gonioscopy. The flattening of iris profile after iridotomy confirms the pupillary block mechanism (3).

The pupillary block mechanism is clearly visualized by the UBM (Figure 7).

Plateau Iris

Anteriorly placed ciliary processes can be demonstrated which push the peripheral iris up and prevent the iris root from falling away from the trabecular meshwork after iridotomy (2) (Figure 8).

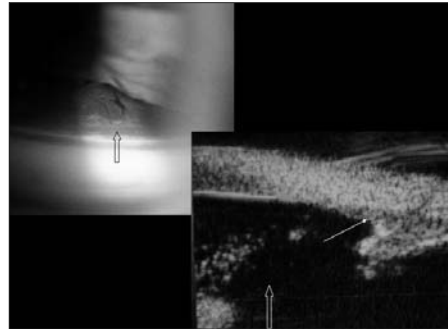


Fig. 6(A): (Left) Gonioscopic photograph of the superior angle of the same eye depicting a widened light colored ciliary body band, characteristic of angle recession, in the area of iridodialysis. (Right) Ultrasound biomicroscopy (UBM) showing the separation between the longitudinal and circular ciliary muscles (white arrow). The vitreous is seen herniating into the anterior chamber (hollow arrow) through the iridodialysis

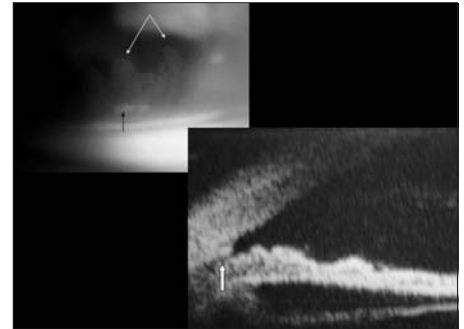


Fig. 6(B): (Left) Gonioscopic photograph of the superior angle showing an area of the sclera visible through the ciliary body suggestive of a cyclodialysis cleft (black arrow). Note the ciliary processes visible through the iridodialysis (white arrows). (Right) Cyclodialysis cleft confirmed on UBM as an echoluscent streak between the sclera and ciliary body (white arrow), just posterior to the scleral spur.

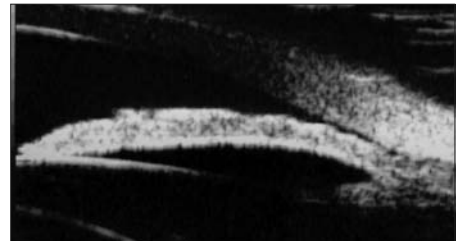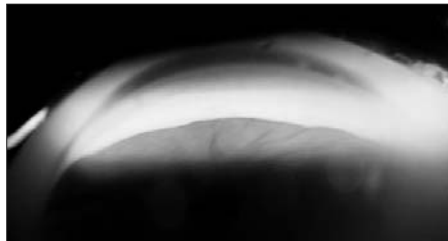


Fig. 7: Pupillary block angle closure seen by gonioscopy (left) and by the UBM (right).

Laser Iridotomy

Laser peripheral iridotomy eliminates pupillary block, allowing the convex iris to flatten and widen the anterior chamber angle (4). The iridotomy and the consequent angle deepening can be nicely demonstrated by the UBM (Figure 9).

Iris and Ciliary Body cyst

UBM is extremely useful in imaging structures behind the peripheral iris, such as ciliary body cysts (Figure 10). The patient whose UBM is depicted here was a 28-year old woman with a secondary angle closure.

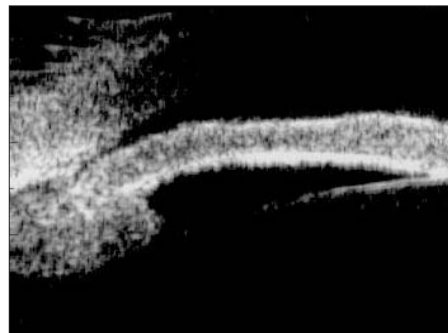

Fig. 8: Plateau iris configuration showing the anteriorly placed ciliary processes pushing the peripheral iris up in the angle.

Conclusions

UBM is a quick, convenient, minimally invasive investigative tool, which is immensely helpful in diagnosing cases such as plateau iris and ciliary body cysts that are difficult to image otherwise. Its limitations include bulky instrumentation and limited penetration into the eye. UBM

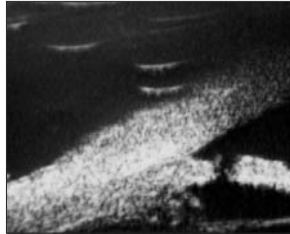
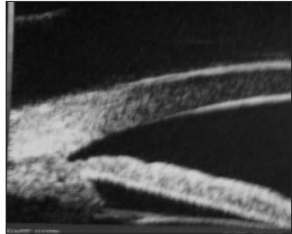
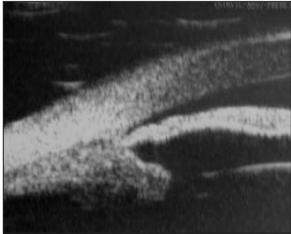

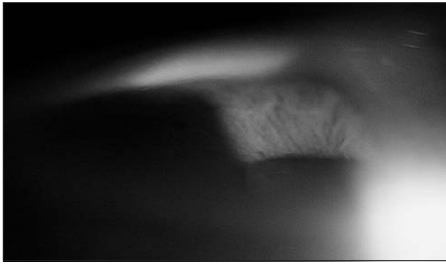


Fig. 9: (Top left) Goniopicture of a closed angle. (Top right) Same angle after a laser iridotomy. (Bottom row) UBM pictures of the same angle before and after the laser iridotomy. (Bottom right) UBM picture showing the iridotomy.

findings, as for all investigations, should never be interpreted in isolation. Keeping the clinical setting in mind is crucial for accurate diagnosis and appropriate management.

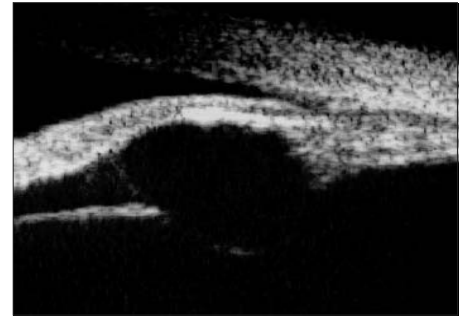


Fig. 10: UBM picture of a ciliary body cyst causing secondary angle closure.

References

1. Pavlin CJ, Harasiewicz K, Sherar MD, Foster S. Clinical use of ultrasound biomicroscopy. *Ophthalmology* 1991;98:287-295.
2. Pavlin CJ, Ritch R, Foster S. Ultrasound biomicroscopy in Plateau Iris Syndrome. *Am J Ophthalmol* 1992;113:390-395.
3. Mandel MA, Pavlin CJ, Weisbrod DJ, Simpson ER. Anterior chamber Depth in Plateau Iris Syndrome and Pupillary Block as measured by ultrasound biomicroscopy. *Am J Ophthalmol* 2003;136:900-903.
4. Gazzard G, Friedman DS, Devereux JG, Chew P, Seah SKL. A Prospective Ultrasound Biomicroscopy Evaluation of changes in Anterior segment Morphology after Laser Iridotomy in Asian eyes. *Ophthalmol* 2003;110:630-638.

Ultrasound Biomicroscope

Shalini Mohan, MS

Ultrasound biomicroscope (UBM) is a recent instrument for in vivo imaging of anterior segment in non-invasive fashion, with the help of high frequency ultrasound transducer. Its strength lies in its ability to produce cross sections of the living eye at microscopic resolution. UBM extends the use of ophthalmic ultrasound in a manner analogous to optical microscopy. Pathophysiological changes involving anterior segment architecture can be evaluated quantitatively and qualitatively. The transducer used for posterior segment evaluation (B-Scan) has a frequency of 10 MHz, therefore probe has greater depth of penetration and a greater resolution. This frequency is ideally suited for the posterior segment as all the structures imaged in the posterior segment have a thickness of more than a millimeter. The anterior segment has a depth of 4-5 mm and the structures are close to each other so a higher frequency probe is required.

Dr. Charles Pavlin, Prof. Stuart and Prof. Foster developed UBM at the Princess Margaret Hospital at Toronto, Canada in 1989. Initially they developed three probes - 50, 80 & 100 Mhz for clinical trials. 80 & 100 MHz probes were used to see the cornea and the anterior chamber as the depth of penetration is only 2 mm. They reached to a conclusion that a 50 MHz is an ideal compromise between depth and resolution to visualize the entire anterior segment. They published the first papers on UBM in 1990. The first commercially available machine was developed by Zeiss in 1991. It is now available with Paradigm USA.

Instrument

It mainly consists of hard disc, video monitor, mouse, probe, foot switch, zip/floppy drive, foot switch and printer. There are three main components of the **hard disc** of the UBM machine.

1. Transducer
2. High-frequency signal processing.
3. Precise motion control

UBM incorporates 50 MHz – 100 MHz polymers *transducers* which are incorporated in a B-mode clinical scanner. The transducer is mounted on a pulley with the piezoelectric crystal fixed on a large handle.

R.P. Centre, AIIMS,
New Delhi

The commercially available unit has a 50 MHz **probe**, which provides lateral and axial resolution of 50 microns and 25 microns, respectively and the depth of penetration is 4 -5 mm. This means that a radiofrequency pulse of 50 MHz is produced by the piezoelectric crystal of the transducer. This radiofrequency travels the body tissue and is reflected back to the transducer.

The polymer transducers are incorporated in a probe. In the Paradigm instruments UBM, the probe is suspended from a gantry arm to minimize motion artifacts and lateral distortion is minimized by a linear scan format. In OTI (Ophthalmic Technologies, Toronto Canada) device the probe is small and light enough not to require suspension of arm and a sector scanning method is used.

Normal B-scan transducer has oil filled covering with a membrane over the piezoelectric crystals. The penetration of the 50 MHz UBM transducer is poor, hence the transducer has an open crystal and there is no membrane covering the crystal to avoid signal loss. Therefore excessive contact between the globe and the moving transducers must be avoided to prevent abrasions. Pavlin et al developed the transducers with long focal length (6-10 mm) which provides a long working distance and minimizes the possibility of the eye contact.

The reflected radio frequency is processed by the *signal processing unit*. The signal processing unit in UBM is specially designed to handle high frequency signals.

In UBM the movements of the transducer have to be subtle to scan adjacent areas in the anterior segment. During normal B-scan the movement of the transducer is over a wide area covering the entire eyeball. To enable this subtle movement there is a special *motion control device* for the transducer.

The scanner provides a 4 x4 mm field with 256 vertical image lines (or A –Scan) at a rate of 5 frames per second. Each A –scan is mapped into over sampled 1024 points, with 256 gray – scale levels representing the logged amplitude of reflection and then the number of points is down sized to 432 pixels to fit into the UBM monitor. The UBM uses a speed of sound constant of 1500 m/s to convert time to distance measurements. The UBM machine is equipped with software so that gain, time of gain and delay can be adjusted.

The **video monitor**, on which the real time image is displayed, can be recorded on videotape for later analysis. The markings on the right side of the scan are at 0.5 mm intervals.

Series of **eye cups** (Fig 1) have are provided with the machine to create a water bath for the coupling agent. These special cups fits in between the eyelids, keeping them open. Recently Kapetansky et al have developed an improved water bath for UBM. They have designed a beveled, oval-shaped eyecup molded from a medical-grade polymer with a round fluid reservoir fused to the top of it. This new design addresses the problem of saline leaking out from under the water bath, improves comfort for patients with various lid fissures, and increases room for oscillations of the ultrasound probe.



Fig. 1: Eyecups

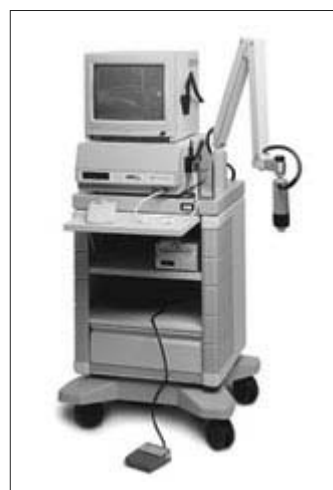

Fig. 2: P 40 UBM

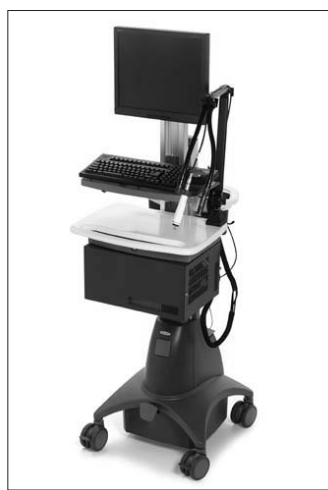

Fig. 3: P60 UBM

The **foot switch** provided with the machine helps in capturing the images. Zip/floopy drive can be used to transfer the images and print out can be taken with the help of printer.

Functional Modalities

The basic functional modalities of UBM include:

- ♦ **B mode** provides two-dimensional images of the organs such as eye and tumor, for the morphological and dimensional observation.
- ♦ **M mode** displays the dynamic position change of moving structures such as iris with accommodation.
- ♦ **3D reconstruction** can acquire a three-dimensional volume data set of the structure of interest, measure the tissue volume, and demonstrate the surface image of the structures inside the body.

Besides these, the two important modes used specially in the non-ophthalmic set-up are

- ♦ **Doppler mode** measures the blood flow velocity at the site of interest in the cardiovascular system.
- ♦ **EKV** (ECG based Kilo-Hertz Visualization) technology can retrospectively reconstruct a two-dimensional cardiac image which equals that acquired at the frame rate of 1000 Hz. It is suitable for evaluating the left ventricular wall motion and valvular movement.

Availability of Ultrasound Biomicroscopic Instrumentation

The machine is available with following companies:

1. Paradigm

The commercial instrument based on original design was developed in the research laboratories of Humphrey Instruments which was later sold to Zeiss Instruments. Recently the manufacture of the instrumentation has been taken over by Paradigm Industries.

- ♦ P40 machine (Fig 2) – is the original machine having 50 MHz frequency probe. This machine uses icon-based, user friendly, proprietary software for faster and more accurate examinations. On-screen icons, prompts, and help screens assist the operator in using the system. Intraocular anatomy and pathology in detail can be compared with past examinations. UBM images are stored on the hard drive and can be archived on standard floppy disks or a Zip drive. Additional superior features include dual calipers, complete on-screen annotation, pre/post processing capabilities, as well as zoom and pan features for optimal positioning for viewing suspicious areas.
- ♦ P45 machine - The P45 Ultrasonic Workstation provides the highest ultrasound resolution for imaging.

- ♦ P60 machine (Fig 3) – This is the next generation of Ultrasonic Biomicroscope. It provides unprecedented image accuracy and flexibility with 12.5MHz, 20MHz, 35MHz and 50MHz probes.

The advantages are:

- Full Sulcus-to-Sulcus imaging
- Water path probe
- High resolution still image and live video capture

It can be used with Windows XP operating systems, provides exceptional platform stability and ease of use as well as full network capabilities to transfer and save patient images and videos.

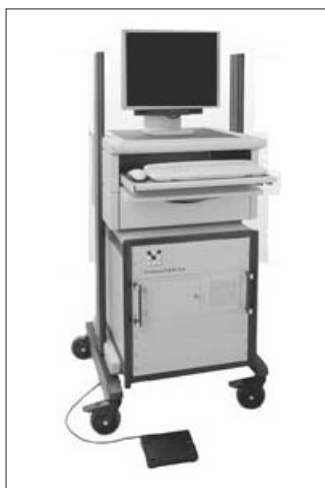

Fig. 4: 3 D UBM

Display Functions

- Dual Calipers
- Angle Measurement
- Area Measurement
- Area Zoom

Image Capture

- JPG Photo Format
- AVI Movie Format

Image Storage

- 80 GB IDE Hard Drive
- DVD CD-R/W Drive

2. Innovative Imaging

A lower frequency instrument is available as an add-on to the regular 10 MHz scanner developed by Innovative Imaging. It does not have the resolution of the original instrument, but does have the advantage of a relatively cheap price and a better image than that obtainable by using a 10 MHz scanner and a waterbath.

All units include

- 10 second Movie Mode
- Windows operating system with new graphical user interface
- Multiple USB 2.0 ports
- Patient image database
- High resolution display with 256 shade gray scale
- Gain control on frozen and recalled images
- Network-ready

3. Rion Japan

This instrument is only available in Japan, but has quite good images.

3D UBM

Advances in 3D imaging provide users with convenience and flexibility of viewing the tissue of interest as a whole organ in different orientations. 3D ultrasonography allows the precise assessment of three-dimensional structures. For 3D UBM (Fig 4) imaging sets of consecutive 2D images parallel planes are acquired at

spacing of 33 microns for complete length of tissue. These are constructed into 3D views via segmentation analysis and texture mapping technique. The 3D UBM is a reliable tool for estimating volume.

The three views seen are:

1. Cube view: The 3D image is presented as a polyhedron that can be rotated in any of the 6 planes.

2. Cross view: The resulting image is presented as 3 planes perpendicular to each of x, y and z axes.

3. Surface view: The resulting 3D volume is presented in the surface view. First the boundary is drawn manually and the area is measured by determining the number of pixels within the counter. The volume of the mass can be calculated by multiplying the total area of outlined boundaries by interslice distance.

The color-encoded region shows concentration (-2 to +12 decibels) with a non-linear color look-up table.

The advantage of tumor volume determination is for follow-up of patients (progression, regression) and for planning the treatment before kryo, hyperthermia or irradiation. It also provides exact foreign body localization and useful topographic information in case of orbital tumors. It is extremely useful images for teaching purposes but it is not applicable in a book unless using colour coding possibilities or stereoscopic image-pairs. As the 3D tissue data can be stored on hard disc, the whole examination process can be repeated and demonstrated or the volume data can be re-examined at any later date.

The 3D reconstruction and visualization tool is available in commercial scanners (Veve 660, Visual Sonics Inc)

References

1. Sherer Md, Starkoski BG, TaylorWB, Foster FS. : A 100 Mhz B-scan ultrasound backscatter microscope. *Ultrasound Imaging* 1989; 11 95-105.
2. Pavlin CJ, Sherar MS, Foster FS. Sub- Surface ultrasound biomicroscopy of the intact eye: *Ophthalmology* 1990; 97: 244-250.
3. Palvin CJ, Harasiwicz K, Sherar MS, Foster MS: Clinical use of Ultrasound Biomicroscopy. : *Ophthalmology* 1991: 98: 287-295.
4. Ishikawa H, Schuman JS. Anterior segment imaging: ultrasound biomicroscopy. *Ophthalmol Clin North Am.* 2004 Mar;17(1):7-20.
5. Kapetansky FM. An improved water bath for ultrasound biomicroscopy. *Ophthalmic Surg Lasers Imaging.* 2005 Nov-Dec;36(6):523-5.
6. Cheung A MY, Brown AS, Hastie LA, Vivienne C, Roy M, Lacfield JC et al. Three dimensional ultrasound biomicroscopy for xenograft growth analysis. *Ultrasound in Med & Biol.* 2005; 31(6):865-870.

Poison as Cure: Therapeutic uses of the Botulinum Toxin

Bali Jatinder, MS

History and introduction

Botulinum toxin is the most potent toxin known. It is readily absorbed from mucosal surfaces. Apprehensions have been expressed about its possible use as an agent in bioterrorism and biological warfare. If dispersed as an aerosol or mixed in the food or water it can lead to a large outbreak of botulism. The disease presents as a symmetric descending paralysis in an afebrile patient. Cranial nerve involvement with diplopia, dysarthria, dysphonia, dysphagia and respiratory paralysis is seen after a variable incubation period. The treatment is mainly supportive. Bivalent equine antitoxin (against types A and B), monovalent antitoxin (against type E) and a trivalent antitoxin have been used in the treatment. A pentavalent vaccine is available for use in exposure prone individuals.

The source of the toxin is *Clostridium botulinum*, an anaerobic gram-positive spore forming organism. It is found in marine and soil environments all over the world. On the basis of antigenic specificity of its toxin it has been divided into 8 types A, B, C, D, E, F and G. In addition to *Clostridium botulinum* some other species of *Clostridium* like *C. butyricum* and *C. baratii* also produce the toxin. The toxin is heat labile and can be inactivated by heating at 100 °C for 10 minutes. The toxin enters the bloodstream and gets transported to the peripheral cholinergic nerve terminals at the neuromuscular junctions, postganglionic parasympathetic ganglia, etc. It affects the transmitter release by acting on exocytosis. The toxin has found clinical uses in various disciplines of medicine. *Clostridium botulinum* was identified by the Belgian Professor Emile Pierre van Ermengem as the cause of botulism in 1895 AD. Dr. Herman Sommer in 1926 produced a crude form of botulinum toxin A in 1926. Dr. Edward Schantz first produced purified toxin A in 1946. Burgen et al in 1949 demonstrated that botulinum toxin blocks neuromuscular transmission. In late nineteen seventies botulinum toxin was used by Dr Alan Scott by injection into the extraocular muscles for correction of strabismus. In the eighties randomized double controlled studies showed the therapeutic efficacy of BTX-A for focal dystonia, adductor spasmodic dysphonia, oromandibular dystonia, abductor spasmodic dysphonia, etc. In December 1989, the U.S. Food

and Drug Administration approved BTX type A for the treatment of strabismus, blepharospasm, and hemifacial spasm in patients 12 years of age and older.

Physical characteristics

Seven antigenically (immunologically) distinct neurotoxins are recognized, labeled types A, B, C, D, E, F, and G. Types A, B, E and F cause human intoxication. Types C and D affect livestock and other animals. No outbreaks have been reported with type G. Each toxin consists of a light and a heavy chain bonded together covalently by disulphide bond. Non-toxic surface proteins cover these.

The chain is cleaved one-third from the N- terminus to create a light chain. The light chain is bonded covalently to the heavy chain. The complex then experiences cleavage at the C- terminus of the heavy chain inside the bacterium. Nontoxic surface proteins produced by the bacterium surround these toxins.

BTX type A and type B are the main serotypes commercially available for clinical use. Clinical experience is emerging also with BTX types B, C, and F. BTX-A has been in clinical use for almost two decades, with an outstanding efficacy and safety profile.

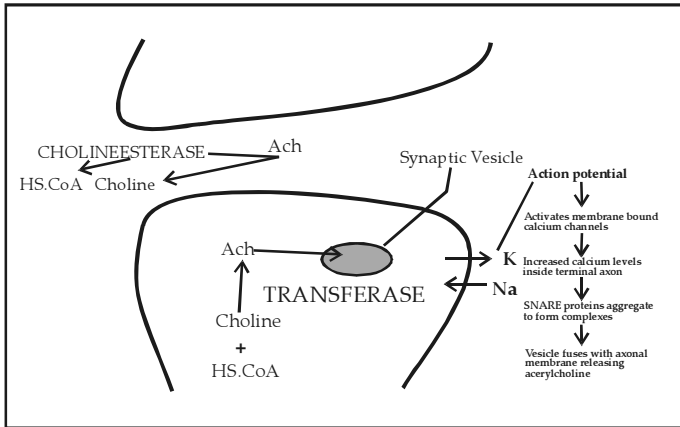
Clinical effects are often seen within 1 week of injection, and benefits typically last from 3-6 months.

Property	Toxin A	Toxin B
Length	1295 amino acids	1290 amino acids
Molecular weight without surface proteins	149.3kd	150.6kd
With surface proteins	900kd	700kd

Mechanism of action

The toxins inhibit the release of acetylcholine at the terminals of cholinergic neurons at the neuromuscular junction. With the propagation of action potential, there is activation of membrane bound calcium channels. The increased levels of the calcium cause the SNARE proteins to aggregate and form complexes. This causes the fusion of the vesicle containing acetylcholine with the synaptic membrane. The acetylcholine is released into the neuromuscular junction. The toxins inhibit the aggregation

Hindu Rao Hospital,
Delhi



SNARE targets of different Botulinum toxin serotypes

and complex formation of the SNARE Proteins.

Toxin	Target
A,E	Synaptosomal Associated Protein (SNAP25)
B,D,F,G	Synaptobrevin / Vesicle associated membrane protein (VAMP)
C	Syntaxin

Commercial preparations

Preparation	Presentation	Remarks
Botox R	100U of sterile vacuum dried solid. Must be kept at -5°C.	BTX type A. Hall strain of Clostridium difficile type A
Dysport ^R	Freeze dried solid	BTX type A
Myobloc	Liquid with concentration of 5000 IU/ml	BTX type B. Bean strain of Clostridium difficile type B.

1. Botox^R purified neurotoxin complex is a sterile, vacuum dried extract produced by Hall strain of Clostridium difficile type A. Each vial contains 100 units (U) of Clostridium botulinum type A neurotoxin, 0.5mg human albumin and 0.9 mg of sodium chloride as a lyophilized solid.
2. Dysport^R purified neurotoxin complex is a sterile, vacuum dried extract. It is marketed in the UK.
3. Myobloc^R is marketed as a slightly acidic liquid (pH=5.6) with concentration of 5000U/ml. It is produced from the Bean strain of Clostridium difficile type B. The dried complexes were originally dissolved in preservative free saline for use. They were kept

refrigerated and used within 4 hours of reconstitution. However, now reports show that dried toxin can be reconstituted with preserved saline and the shelf life increases to 30 days under appropriate storage conditions.

The liquid formulation of BTX type B (Myobloc^R) can be diluted with preservative free saline. The main indication of the latter is development of antibodies to type A. It also appears to have a lower diffusion capacity as compared to type A preparations.

Indications of Botulinum Toxin

The Food and Drug Administration has approved it for the treatment of blepharospasm, glabellar rhytides, hemifacial spasm, cervical dystonia and strabismus. It has been used to treat acquired nystagmus and oscillopsia. Paralysis of the lacrimal pump by orbicularis injection has been used for treatment of dry eye. Injection into the lacrimal gland can be used to treat hyperlacrimation secondary to aberrant facial nerve regeneration by inhibition of acetylcholine release at postganglionic nerve ending.

Local injection of the toxin results in improvement of migraine, probably through the inhibition of release of vasogenic factors like substance P, vasoactive intestinal peptide and neuropeptide Y by the same mechanisms as ACh release. Another interesting application described is its use to alleviate muscle spasm in upper motor neuron lesions.

Other involuntary muscular contractions successfully treated with BTX include palatal myoclonus, achalasia, gustatory sweating, tennis elbow, sphincter disorders such as detrusor-sphincter dyssynergia, anismus associated with intractable constipation caused by spasm of the rectal sphincter and vaginismus.

Ocular Uses of Botulinum Toxin

Blepharospasm

In 1987 Fahn et al reported the first double blind, placebo - controlled trial of BTX, establishing the safety and efficacy of BTX in the treatment of this form of focal dystonia. Numerous subsequent reports confirmed the beneficial effects of BTX when injected into the eyebrows and the orbicularis oculi. The average dose of BOTOX[®] (Allergan) is 10 U in each eyebrow and 10 U in the upper eyelid and 5 U in the lower eyelid. Injection of BTX into the pretarsal, rather than the preseptal portion of the orbicularis oculi is more effective and is associated with lower frequency of ptosis, the most common complication of this treatment. Over 90% of patients of blepharospasm improve with this treatment. In addition to observed functional improvements, such as improved ability to read,

Main Clinical Applications of Botulinum Toxin are summarized below

<i>Focal Dystonias</i>	<i>Other Inappropriate Contractions</i>
Blepharospasm	Bruxism (TMJ)
Cervical dystonia (torticollis)	Lumbosacral strain and back spasms
Laryngeal dystonia (spasmodic dysphonia)	Myokymia
Muscle contraction headaches	Nystagmus
Oromandibular-facial-lingual dystonia	Other spastic disorders
Other focal dystonias (idiopathic, secondary)	Painful rigidity
Task-specific dystonia (occupational cramps)	Radiculopathy with secondary muscle spasm
Other Involuntary Movements	Spastic bladder
Hemifacial spasm	Spasticity
Palatal myoclonus	Strabismus
Pelviorectal spasms (anismus, vaginismus)	Stuttering
Tics Achalasia (esophageal)	
Voice, head, and limb tremor	
Other Applications	
Cosmetic (wrinkles, facial asymmetry), Debarking dogs, Essential hyperhidrosis, Protective ptosis	

to 8 months in some cases. The clinical benefit does not appear to wane with time.

Complications

10% of patients experience complications, such as ptosis, blurring of vision or diplopia, tearing and local hematoma. Complications usually improve spontaneously in less than 2 weeks. Ptosis and other complications can usually be prevented by initially injecting only 5 U in the lateral portion of the upper lid and 5 U medially. The complication rate is reported to decrease after repeat BTX treatments.

Hemifacial Spasm

Hemifacial spasm is defined as a neurologic disorder manifested by involuntary, recurrent twitches of the eyelids, perinasal, perioral, zygomaticus, platysma, and other muscles of only one side of the face. Hemifacial spasm is not only annoying, but also socially embarrassing, and in some patients it causes unilateral blepharospasm that can interfere with vision.

Hemifacial spasm is usually due to a compression or irritation of the

drive, or watch TV, there is usually a meaningful amelioration of discomfort and, because of less embarrassment, the patient's self-esteem also frequently improves. The average latency from the time of the injection to the onset of improvement is 4 days.

Girlanda et al have demonstrated that unilateral injection improves bilateral blepharo-spasm, possibly via toxin spread but more likely as a result of some physiological mechanism peculiar to dystonia.

An AAO paper reports that is the treatment of choice for Blepharospasm now considered to be BTX injections by many. In addition to idiopathic blepharospasm, BTX injections have been used effectively in the treatment of blepharospasm induced by drugs (e.g., levodopa in parkinsonian patients or neuroleptics in patients with tardive dystonia), dystonic eyelid and facial tics in patients with Tourette's syndrome, and in patients in whom blepharospasm has been associated with "apraxia of eyelid opening."

The average duration of maximum benefit is 3 months, but the total benefit may last considerably longer, up to 6

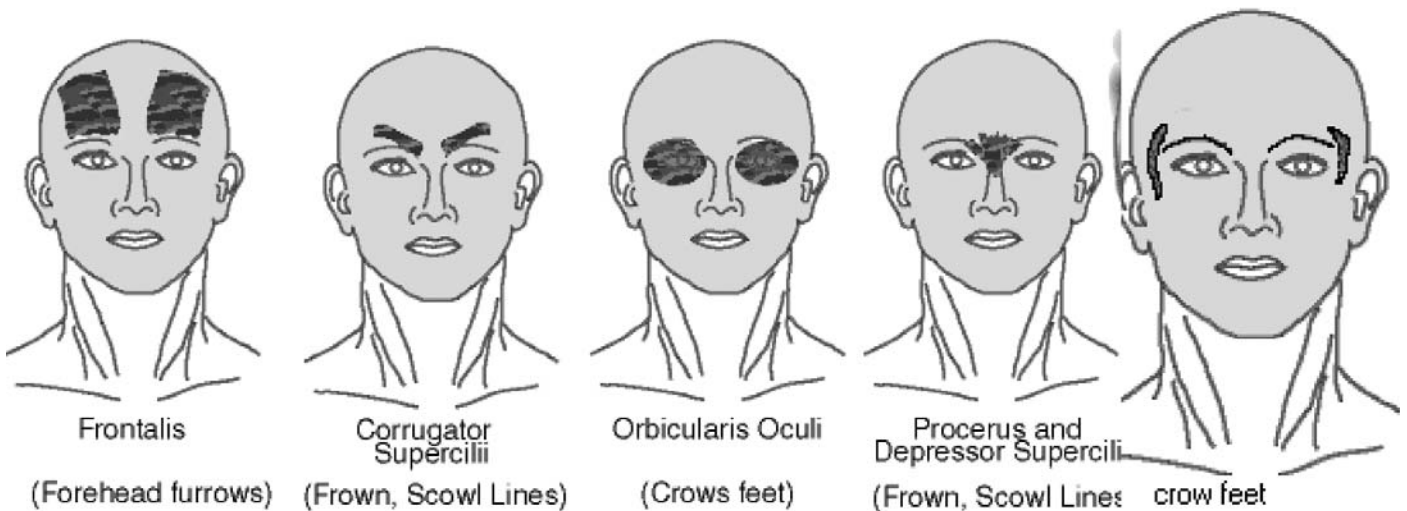
facial nerve by an aberrant artery or abnormal vasculature a round the brain stem. Microvascular decompression of the facial nerve has a high success rate. This surgical treatment also carries some serious risks, such as permanent facial paralysis, deafness, stroke, or death.

Local injections of BTX into involved facial muscles offer a useful alternative to surgical therapy. Nearly all patients improve, the complications are minimal and transient, and the approach can be individualized by injecting only those muscles whose contractions are most disturbing to the patient.

The average duration of improvement of hemifacial spasm is about 5 months. There are usually no complications other than transient facial weakness. The FDA has approved BTX injections for hemifacial spasm, in addition to its indication for blepharospasm. Clinical effects are seen within 1 week of injection and the benefits last 3-6 months.

BTX in cosmetic applications

There has been growing interest in the use of BTX in



cosmetic applications, such as correction of wrinkles, crowfeet and frown lines. The usual dose used is 4-5 U that is injected subcutaneously. The various sites of injection being used by practitioners are as follows. (Other methods of injection are also being used and the present article touches on some of the techniques in use)

indications of BTX therapy will, in all probability, continue to expand in the future. Less than 5% of those treated for cervical dystonia and only rare patients treated for other disorders have become resistant through development of blocking antibodies. Hence it is an exciting treatment modality.

Complications

It is generally safe and well tolerated. The most common adverse effect is the extension of effect outside the intended area. This occurs due to diffusion and lack of comparability of doses. With lower doses its effects are not much pronounced. No satisfactory solution to the problem of diffusion exists at present. Recent reports indicate Botulinum toxin B has lesser diffusion rates in animal studies. Ptosis and paralytic ectropion hence are common side effects in ocular practice. With larger doses (600-900 U as used in cervical dystonia) generalized weakness has also been reported.

The side effects are transient and usually self-limiting. Often they will require no more than reassurance or supportive treatment.

Anaphylaxis and rashes may occasionally occur.

Contraindications of Botulinum toxin use

Any history of neuromuscular disease like myasthenia, pregnancy and lactation are absolute contraindications for BTX use. Concurrent use with drugs that interfere with neuromuscular junction function like aminoglycosides is a relative contraindication.

The future

The safety, effectiveness, specificity and reversibility of BTX have made it a powerful and versatile tool. The

Normal Tension Glaucoma: A Case

Harsh Kumar MD, Archana Chafle

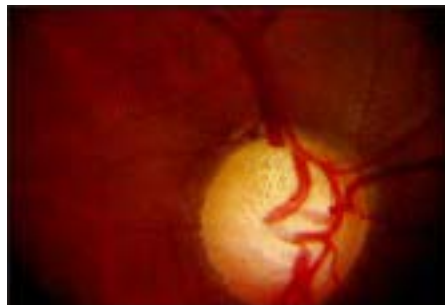
In Jan 2004 a 57 years old male patient walks in for routine eye checkup. There is history of decreased vision in the left eye since childhood and h/o using glasses. There is no past h/o any acute eye problem, any systemic illness or drug allergy.

The patient was examined in detail. His V/A was 6/6 (+1.0 DS) OD and 6/18 (+2.25 DS/ +1.25 CYL 30) OS. The slit-lamp examination was normal. The IOP in both the eyes was 18 mm Hg. The retina revealed a cup to disc ratio of 0.6 in the right eye with laminar dot sign, superior notching and bayoneting sign while the left eye showed tilted disc with C:D 0.6, inferior notch and peripapillary atrophy.

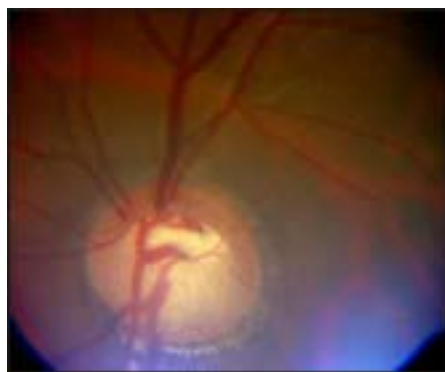
The patient was investigated for glaucoma. The diurnal variation was within normal range (14-18mm). The gonioscopy showed open angles in both eyes. The central corneal thickness was 561 and 563 microns in the right and the left eyes respectively examination on a Humphrey with a Sita Standard 30-2 programme revealed inferior arcuate scotoma in the right eye while the left eye showed superior field defects encroaching on the fixation. The field was repeated after 2 days and no significant learning changes were detected.

Provisional diagnosis of NTG was kept. Since it is a diagnosis by exclusion, we ruled out the history of any steroid intake or eye-injury in the past. There was no history of any episode of acute blood-loss or shock like condition in the past or of any cardiac problem.

Investigations for nocturnal hypotension was carried out but failed to reveal anything significant. The routine haemogram and ESR were within normal limits. The only abnormality in the lipid profile was slightly high cholesterol. Color Doppler was normal. The MRI to rule



Fundus right eye



Fundus photo left eye

out any compressive Optic Nerve damage did not reveal anything significant.

The patient was treated as a case of NTG as the field changes were typical of glaucoma and the field defects were encroaching on the fixation. The patient was initiated on Xalatan eye drops HS in both eyes. He was explained about the nature of the disease and the slow progression and irreversibility of the field damage. The patient was advised to follow up after 6 months for IOP and visual fields. He was to contact some local ophthalmologist for an IOP check after a month to see the efficacy of topical drops to reduce IOP by 30%.

The patient came for review in May 2005 i.e. 16 months after the initial check-up. The patient being out-station and having no obvious visual problems stopped the medications 10 months back. He still does not face any

problems.

The patient was checked again. The V/A OD was 6/6 (+1.25 DS) OS 6/18(+2.25DS/+1.25 CYL 30). The IOP in right eye was 17 and 19 mm in the left eye. The angles were open, retina showed same changes as last time (no progression of cupping). The visual fields showed same defects with no progression of field defects.

This is a typical case of Normal Tension Glaucoma which one should treat. The indications for starting the treatment in this case are

1. Field defect threatening fixation
2. The IOPs in higher range 16-18 mm

The NTG is a diagnosis by exclusion. The other conditions to be ruled out include:

1. **Undetected glaucomas:**
 - ◆ POAG with diurnal variation +ve
 - ◆ Intermittent IOP elevation
 - Angle Closure glaucoma
 - Glaucomatocyclitic crisis
 - ◆ Previously elevated IOP

Glaucoma Services

Center for Sight, Safdarjung Enclave,
New Delhi

- Old secondary glaucoma e.g., steroid induced glaucoma, uveitic glaucoma, pigmentary glaucoma
- Normalized IOP in an eye with previously elevated IOP
- ◆ Use of medication that may cause IOP lowering (systemic beta blockers)



2. Non-glaucomatous Optic Nerve Disease

- ◆ Congenital anomalies (coloboma, optic nerve pits)
- ◆ Compressive lesions of optic nerve and chiasm
- ◆ Shock optic neuropathy
- ◆ Anterior ischemic optic neuropathy
- ◆ Optic nerve drusen

The indications of treatment in case of NTG are:

- ◆ Visual Fields Threatening fixation
- ◆ IOP in higher ranges - 16-20
- ◆ Splinter Hemorrhage
- ◆ Documented progression of Field defects or Optic Disc Cupping
- ◆ Risk factors like females & history of migraine

If there is no such indication then follow-up 6 mthly to yearly and if



- disc changes
- field changes gets worse
- disc hemorrhage makes fresh appearance then decide for therapy.

Therapy for NTG can be difficult and controversial. The results of the Collaborative NTG Study support aggressive reduction of IOP by about 30% to reduce progressive visual field loss. This can be managed medically or surgically.

The medical therapy is the most common initial approach in the treatment of NTG. It involves the use of Alphagan or Latanoprost. The beta-blockers are particularly contraindicated in these cases for chances of hypotension caused by them.

If medications are inadequate in controlling the IOP, laser trabeculoplasty or filtering surgery are indicated.

However before starting any therapy always remember that you have ruled out all problems that can cause a similar situation, also that the patient may remain stable without intervention for a very long time, the intervention by surgery could result in cataract or added complications

and medications may be expensive. Thus take a decision based on what we have discussed above such that neither you nor the patient will regret later.

Endoscopic Surgery for Pituitary Tumours

Satnam Chhabra, MS, M.Ch.

Pituitary tumours are often encountered in ophthalmological practice when these tumours start compressing optic chiasma to produce visual field defects. Most of such tumours would require surgical decompression to restore vision. Endoscopic transnasal transsphenoidal surgery is a minimally invasive technique, which has been developed in last few years to remove pituitary and other sellar tumours. It facilitates faster postoperative recovery by avoiding any traditional incision and post-operative nasal packing. Thus patients are very comfortable after surgery and have a good visual recovery. Hospitalisation is significantly shortened and many patients require just an overnight stay after surgery. Endoscopic surgery provides a panoramic view of the sphenoid sinus thus obviates many complications and helps in better tumour clearance; intra-operative image intensifier is not required. We have operated 76 pituitary and other sellar tumours endoscopically. There were 66 patients with macroadenomas and 2 patient with microadenoma, two cases of tuberculosis, two cases of fungal granuloma and one epidermoid tumour, one craniopharyngioma and two patients of chordoma. Most of the patients had an uneventful recovery.

Pituitary tumours are common lesions with an incidence of about 8 to 14 per lac of population and account for about 10 to 15 % of all primary brain tumours. Most of these tumours are benign and generally present in one of the three ways. The most common presentation is usually loss of visual field and acuity due to compression on the optic chiasm. Up to 50 -90 % of patients with pituitary

tumours have been reported to have visual loss in different series. Therefore, in clinical practice all the patients showing loss of visual acuity and visual field defect should be examined carefully and after exclusion of ocular diseases, the neurological causes should be ruled out.

Other common presentation is that of overproduction of various pituitary hormones viz: growth hormone, cortisol, prolactin. These patients can present with symptoms and signs of acromegaly, infertility, loss of libido, menstrual disturbances, galactorrhea, cushings syndrome etc. Headache is an uncommon symptom of pituitary tumours.

Majority of patients with pituitary tumour require surgical treatment in the form of either a craniotomy or transsphenoidal removal of tumour. Pituitary tumours are usually treated by transsphenoidal approach for several reasons: It is a less invasive operation, the surgeons comes straight down to the tumour, can preserve the normal pituitary tissue, there is negligible risk of epilepsy and recovery of vision and visual field defect is quicker because optic nerves and chiasm are not manipulated. In some circumstances transsphenoidal surgery is contraindicated or insufficient. The procedure is insufficient when surgery fails to remove adequate amount of tumour particularly to decompress the optic chiasm. The alternative in such cases is the trans cranial approach.

Microsurgical transsphenoidal surgery for pituitary adenoma has been the standard treatment for decades in neurosurgery. Among different techniques for transsphenoidal pituitary surgery the sublabial transseptal approach and the transnasal trans-septal approaches are used most commonly. With microscope, despite magnification, injuries to the carotid artery and optic nerves, although uncommon, still remain potential complications during transsphenoidal pituitary surgery because structures beyond the tubular retractor cannot be seen.

Endoscopic approach is the further advancement of microscopic transsphenoidal approach with several operative and postoperative advantages. Carrau & Jho reported their technique of transnasal transsphenoidal endoscopic surgery of the pituitary gland in 1996. They did not use any retractor and their approach was between the nasal septum and middle turbinate. We

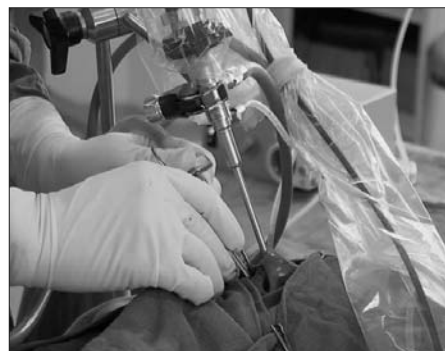
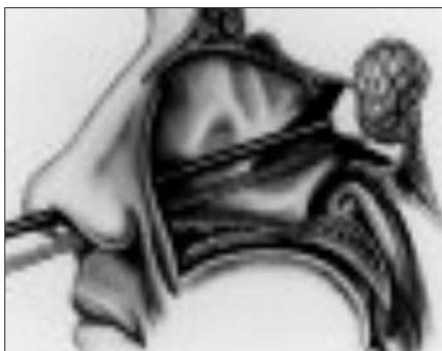
Fig. 1 & 2: Endoscopic transnasal transsphenoidal surgery

Consultant Neurosurgeon

Sir Ganga Ram Hospital,
New Delhi

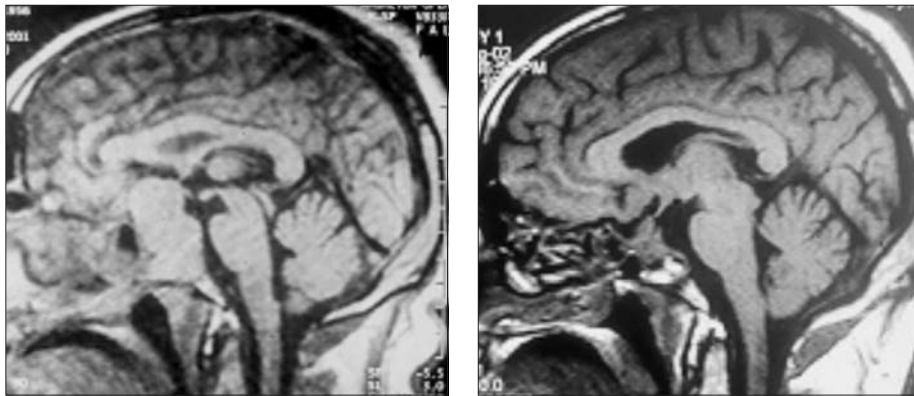


Fig. 3: Pituitary tumour: Before & after endoscopic surgery⁴

have followed the technique described by Jho & Carrau. Since then many other authors have reported their experience with endoscopic pituitary surgery viz: Jho & Carrau, Sethi & Pillay, Cappabianca & Divitiis et al.

In this technique the endoscope and other instruments are passed through one of the nostrils, whichever is wider (Fig.1 & 2). The sphenoid sinus is opened at the posterior end of nasal passage under endoscopic vision without any mucosal dissection in the nasal passage. After entering the sphenoid sinus, bone of sellar floor is removed and an opening is made in the dura covering the pituitary tumour. Then the tumour is removed with suction and curettes under direct endoscopic vision. One can introduce the endoscope inside the sella to remove tumour from hidden corners. Since there is no dissection in the nasal cavity no postoperative packing is required.

Patients are kept in regular ward after surgery and ICU is not required. Postoperative discomfort is minimal and often does not require strong analgesics. Patients are observed for any nasal bleeding, CSF leak, or any signs of diabetes insipidus. Patients may be discharged next day if they are stable.

We have operated 76 patients with sellar tumours endoscopically. There were 48 males and 28 females, ranging in age from 29 to 74 years. 68 had pituitary adenoma out of which 2 had microadenoma with acromegaly, 66 others were macroadenoma (Fig.3 & 4). 51 were nonfunctional adenoma, 12 had acromegaly, 5 prolactinoma. There was no patient with cushing's disease. 2 Patients presented pituitary apoplexy with headache and other cranial nerve palsies. One female patient had a large parasagittal meningioma and a small pituitary adenoma. In first stage, Meningioma was removed and in second stage after one week pituitary adenoma was removed endoscopically through transnasal route.

Two patients had clival chordoma, the first patient had a very large clival chordoma (Fig.5) who presented with nasal bleeding.. One patient had epidermoid tumour, he presented with severe hypernatremia and acute renal

failure due to diabetes insipidus. Two patients had tuberculosis of pituitary gland and two patients had fungal granuloma of pituitary. These patients presented with severe headache.

Most of the patients had a very comfortable and uneventful postoperative period. No patient had any significant bleeding from nose. All of them had normal unobstructed airways. There was minimal pain. Only few required analgesics. 18 patients were discharged next day

following surgery. Other patients stayed for 3-4 days due to various social or other minor problems. Among 51 patients with nonsecreting adenomas, 24 underwent total resection, 18 near total resection and 9 patients had partial tumour resection only, because tumour was very firm. 12 were given radiotherapy after surgery. Of the nonsecreting adenomas, 41 presented with progressive visual impairment, all of them showed improvement in their vision and visual fields following surgery. Patients with pituitary apoplexy recovered completely after surgery over a period of time. Patients who presented with endocrinopathies had good outcome quite comparable to other series.

The advantages of endoscopic pituitary surgery over conventional microscopic surgery are that it does not require any sublabial incision or any dissection in the nose; therefore there are no dental or gingival complications. The chances of any sinonasal complications are minimized.

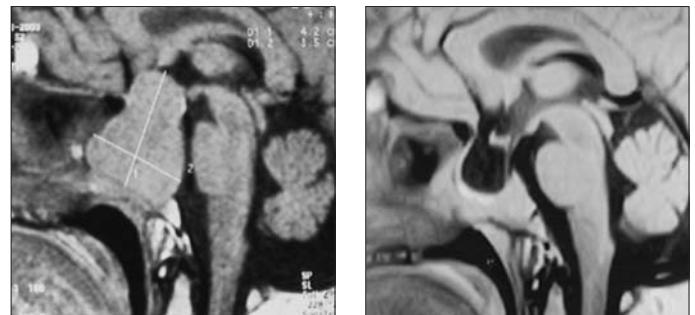


Fig. 4: Pituitary tumour: Before & after endoscopic surgery⁴

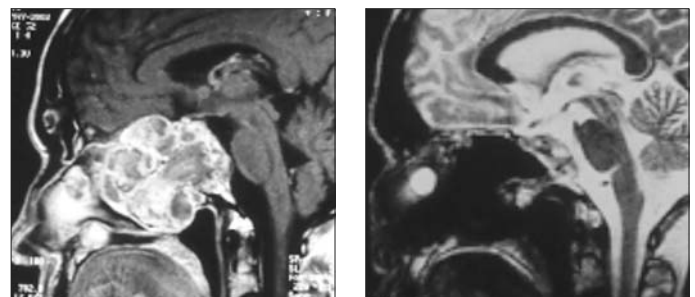


Fig. 5: Clival Chordoma: Before & after endoscopic surgery⁴

Because stripping of sinus mucosa is minimal, normal sinonasal physiology is maintained postoperatively. The anatomical localization of sphenoid sinus is so definite that one doesn't require fluoroscopic C-arm localization. After opening the sphenoid sinus the endoscope provides the panoramic view of the sphenoid sinus demonstrating the bony prominences of the optic nerves and carotid arteries. Therefore the risk of injury to these structures is significantly reduced. Once inside the tumour the angled endoscope enables the removal of tumour from suprasellar area, cavernous sinus, anterior fossa, and posterior fossa under direct visualization. Since there is no dissection in the nose while exposing the tumour, no postoperative nasal packing is required. This leads to more patient comfort after surgery, quick recovery, and early discharge from the hospital. In fact most patients can go home next day. In first 20 patients our ENT colleague was associated with us in performing the nasal and sphenoid part of surgery but when sufficient experience was gained, next 56 patients were operated by neurosurgeon alone from endoscopic exposure to removal of the tumour.

In our experience of 76 patients of endoscopic transsphenoidal surgery, the endocrinological outcome and completeness of tumour removal were quite comparable to the results of transsphenoidal approach, as reported in other studies viz: Tyrrell et al, Shimon et al, Freda et al and Zada et al.

Bibliography

1. Cappabianca P, Cavallo LM, Divititiis Ed, et.al. : Endoscopic Endonasal Transsphenoidal Approach: Outcome analysis of 100 consecutive procedures. *Minimal Invasive Neurosurgery* 2002; 45:193-200
2. Carrau RL, Jho HD, Ko Y: Trans nasal-transsphenoidal endoscopic surgery of the pituitary gland. *Laryngoscope* 1996; 106:914-918
3. Freda PU, Wardlaw SL Post KD: Long-term endocrinological follow-up evaluation in 115 patients who underwent transsphenoidal surgery for acromegaly. *J Neurosurgery* 1998; 89: 353-358
4. Jho HD, Carrau RL: Endoscopic endonasal trans sphenoidal surgery: Experience with 50 patients. *J Neurosurgery* 1997; 87:44-51
5. Jho HD: Endoscopic Transsphenoidal Surgery. *Operative Neurosurgical Techniques Vol.1: 385-397,2000*
6. Jho HD, Alfieri.A: Endoscopic endonasal Pituitary Surgery: Evolution of Surgical Technique and Equipment in 150 operations. *Minimal Invasive Neursurgery* 2001; 44:1-12
7. Pillay PK, Leo CW, Sethi DS: Computer-aided/image-guided and video-endoscopic resection of pituitary tumors. *Stereotact. Funct. Neurosurg* 2000; 74(3-4): 203-9
8. Sethi DS, Pillay PK: Endoscopic management of lesions of sella turcica. *J Laryngol Otol* 109: 956-962,1995
9. Shikami AH, Kelly JH: Endoscopic debulking of pituitary tumour. *Am J Otolaryngol* 14:254-256,1993
10. Shimon I, Cohen ZR, Ram Z, Hadani M: Transsphenoidal Surgery for Acromegaly: Endocrinological Follow-up of 98 ppatients. *Neurosurgery* 2001; 48: 1239-1245
11. Tyrrell JB, Lamborn KR, Hannegan LT, Applebury CB, Wilsom CB: Transsphenoidal Microsurgical Therapy of Prolactinoma: Initial outcome and Long Term Results. *Neurosurgery* 1999; 44:254-263
12. Zada G, Kelly DF, Cohen P Wang C, Swerdloff R: Endonasal transsphenoidal approach for pituitary adenomas and other sellar lesions: an assessment of efficacy, safety, and patient impressions