

DOS Times

**Proliferative Diabetic
Retinopathy - Challenges**
241

CONTENTS

EDITORIAL	237	HARDWARE HINTS	
INSTRUCTIONS TO THE AUTHORS	237	♦ Contemporary Laser Photocoagulation Systems for Diabetic Retinopathy	271
CLINICAL DILEMMA	238	Tinku Bali, MS, FRCS, H.K. Tewari, MD, S.N. Jha, MD, Amit Khosla MD, Neeraj Manchanda, DOMS, DNB	
MEDICAL OPHTHALMOLOGY		PHOTO ESSAY	
♦ Proliferative Diabetic Retinopathy - Challenges & Tips	241	♦ Epidermal Nevus Syndrome	276
Lalit Verma, MD, Dinesh Talwar, MD		Navneet Mehrotra MBBS, Sudipta Ghosh DOMS	
♦ Intravitreal Steroids in Retinal Disorders	247	Madhu Karna MS, Satya Karna DO, DNB	
Mohita Sharma M.S., Ruchi Rai M.S., D.N.B.		TURNING POINT	
Angshuman Goswami M.S., D.N.B.		♦ Intelligence and capability are not enough...	279
♦ National Programme for Control of Blindness Schemes	253	G. Venkataswamy	
Govt. of India Ophthalmology		COLUMNS	
SURGICAL OPHTHALMOLOGY		♦ Forthcoming Events	281
♦ Harvesting of Fascia Lata	257	♦ DOS Quiz	283
Ashok K Grover, MD, MNAMS, FRCS,		Saurabh Sawhney, DO, DNB	
Zia Chaudhuri, MS, MNAMS, FRCS, Shaloo Bageja, DNB		TEARSHEET	
♦ Microincision Lenses	261	♦ Principles of Management of Corneal Repair	302
Ashok Garg, MS, Ph.D, ADM, FRSM,		Shaloo Bageja	

Editor-in-chief

Harbansh Lal

Associate Editors

Anita Sethi
Namrata Sharma
Zia Chaudhuri
Ruchi Goel

Assistant Editors

Shaloo Bageja
Gauri Nagpal
Tinku Bali

DOS Correspondents

Piyush Kapur
Sanjeev Mohan
Neeraj Manchanda
Shalini Mohan
Ashima Aggarwal

Editorial Board

Rajvardhan. Azad
V.K. Dada
S.P. Garg
A.K. Grover

V.P. Gupta
S.N. Jha
Kamlesh
Rajinder Khanna
Amit Khosla
K.P.S. Malik
D.K. Mehta
Madan Mohan
Rajiv Mohan

Anita Panda
Sudipto Pakrasi
B. Patanik
Pradeep Sharma
Kirti Singh
L.D. Sota
H.K. Tewari
R.B. Vajpayee
Lalit Verma

DOS Office

Room No. 2225,
2nd Floor New Building,
Sir Ganga Ram Hospital
Rajendra Nagar, New Delhi-110060
Tel. : 91-11-55705229, 52252225
Mob. : 9810239206
Email: dosonline@vsnl.net
Website : www.dosonline.org

Multimedia & Graphic Design by Saurabh Sawhney • Published by Dr. Harbansh Lal for Delhi Ophthalmological Society.
Printed by Paras Printers, 4648/21 Darya Garj, New Delhi-2. Ph. : 23289976, 9811083737



Appasamy Colour

From Darkness to Light



Delhi Ophthalmological Society

DOS Executive

PRESIDENT

Dr. Noshir M. Shroff

Ph.: (O) 26431296 (R) 26468173

(M): 9811032233

E-mail: shroffey@del6.vsnl.net.in

VICE-PRESIDENT

Dr. Mahipal S. Sachdev

Ph.: (O) 51644000 (R) 26146409

(M): 9810046017

E-mail: msachdev@bol.net.in

EDITOR

Dr. Ajay Aurora

Ph.: (R) 95120-2574665

(M): 98102-53256

E-mail: auroraajay@hotmail.com

EXECUTIVE MEMBERS

Dr. Ajay Kumar Agarwal

Ph.: (O) 51602240, (R) 26932013

(M): 9811900600

E-mail: ajay_agarwalk@yahoo.com

Dr. Anureeta Arora

Ph.: (O) 23587665, (R) 29220844

(M): 9818062975

E-mail: dranureetaarora@hotmail.com

Dr. Rajib Mukherjee

Ph.: (O) 26470965, 26470966

(M): 9810054739

E-mail: mukherjee@vsnl.com

Dr. Neeraj Sanduja

Ph.: (O) 23278423, (R) 25619334

(M): 9871289001

E-mail: neerajsanduja@yahoo.com

SECRETARY

Dr. Harbansh Lal

Ph.: (O) 28741412, (R) 28743988

(M): 9810239206

SECRETARIAT

2225, 2nd Floor, New Building,

Sir Ganga Ram Hospital,

Rajender Nagar, New Delhi - 110 060

Ph.: 91-11-55705229, 52252225

E-mail: dosonlin@vsnl.net

Website: www.dosonline.org

LIBRARY OFFICER

Dr. Sudarshan K. Khokhar

Ph.: (O) 26588700, (Extn. 3073)

(R) 26348693, (M): 9810524238

E-mail: skhokhar38@yahoo.com

TREASURER

Dr. Dinesh Talwar

Ph.: (O) 51644000, (R) 26961109

(M): 98103-02298

E-mail: dineshtalwar@yahoo.co.uk

JOINT SECRETARY

Dr. Sanjay Chaudhary

Ph.: (O) 23278423, (R) 23275893

(M): 9871411227

E-mail: drchoudhary@vsnl.com

EX-OFFICIO MEMBER

Dr. Gurbax Singh

Ph.: (O) 22542325, (R) 22543788

(M): 98101-55682

E-mail: contact@eyecureindia.com

Dr. Jeewan S. Titiyal

Ph.: (O) 26588852-65 (Extn. 3146)

(R) 26589817, (M): 98106-49942

E-mail: titiyal@rediffmail.com

Dr. Rakesh Mahajan

Ex-Officio Member

Ph.: (O) 27314660, (R) 27011210

(M): 9312224631

DOS REPRESENTATIVE TO AIOS

Dr. B.P. Guliani

Ph.: (O) 26198126, (R) 2143569

(M): 9810302294

E-mail: gulianibp@hotmail.com

Dr. Kamlesh

Ph.: (O) 23234622, (R) 24648373,

(M): 98112-40575

E-mail: profkam@bol.net.in

THIS ISSUE OF

DOS Times

IS DISTRIBUTED BY



**Syntho
Pharmaceuticals
Pvt. Ltd.**

E-mail: syntho@del3.vsnl.net.in

MAKERS OF:



For Control of Post-Operative
Inflammation & Infection

DEFLOX EYE DROPS

Dexamethasone Phosphate 0.1%
Ofloxacin 0.3%



The 4th Generation
Fluoroquinolone

QUGAT EYE DROPS

Gatifloxacin 0.3%

Clinical Dilemma Management

S.N. Jha MD, H.K. Tewari MD, Amit Khosla MD,
Neeraj Manchanda DOMS, DNB, Tinku Bali MS, FRCS

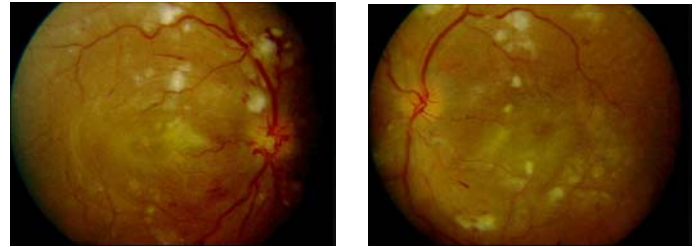
Differential Diagnosis

From the history of the patient we know that the onset of visual loss has been gradual and progressive. The fact that the visual acuity in the right eye is markedly decreased without the presence of RAPD, and with relatively better visual function in the left eye, suggests that retinal odema and not an optic neuropathy is the primary cause of the decreased vision in the right eye.

The fundus examination of the patient shows swollen hyperemic optic discs with peripapillary and posterior pole cotton wool spots, engorged veins, few flame shaped haemorrhages, and macular exudates. The differential diagnosis is that for a patient with bilateral disc edema and cotton wool spots. Cotton wool spots can be a sign of serious systemic disease and are commonly found in retinopathy due to hypertension, diabetes, HIV, collagen vascular diseases such as SLE, dermatomyositis, sclerodema and polyarteritis nodosa, radiation, interferon and anemia. Hypertensive retinopathy presents with a 'dry' retina (few hemorrhages, few exudates, and multiple cotton wool spots) whereas diabetic retinopathy, in comparison, presents with a 'wet' retina (multiple hemorrhage, multiple exudate, extensive edema, and few cotton wool spots).

The differential diagnosis of bilateral disc odema includes elevated intracranial pressure, neuroretinitis, and hypertensive optic neuropathy. Both hypertension and papilloedema can cause macular exudation and peripapillary cotton wool spots. However, in papilloedema they will not be present at the posterior pole. Neuroretinitis is commonly unilateral and cause optic disc odema with a macular star pattern of exudates. Also it is frequently accompanied by cells in the posterior vitreous.

The presence of the cotton wool spots in the arcades is highly suggestive of hypertension as the etiology of the disk edema. In the original Keith and Wagener classification of hypertensive retinopathy, *malignant hypertension* (grade IV) was defined by the presence of papilledema, whereas the term *accelerated hypertension* (grade III) was used when hemorrhages and exudates occurred in the absence of papilledema. However, more recent studies indicate that the prognosis is the same in hypertensive patients with



Hypertensive retinopathy

striate hemorrhages and cotton-wool spots whether or not papilledema is present. In this regard, the World Health Organization has recommended that accelerated hypertension and malignant hypertension be regarded as synonymous terms for the same disease.

In addition, severe bilateral optic disc edema might suggest renovascular hypertension rather than essential hypertension. While malignant hypertension can occur as a part of essential hypertension, in most cases a secondary cause exists. The secondary causes include renal disease, tumors and connective tissue disorders.

The fundus changes in malignant hypertension can be grouped into three categories – hypertensive retinopathy, hypertensive choroidopathy, and hypertensive optic neuropathy. The acute rise in blood pressure causes fibrinoid necrosis of the arterioles and papilloedema. These changes occur primarily at the level of the terminal arterioles and produce vessel dilatation, focal intraretinal transudates, or occlusion that causes cotton wool spots.

Striate hemorrhages are often present in malignant hypertension. These hemorrhages are most commonly observed in a radial arrangement around the optic disc. Striate hemorrhages are a result of bleeding from superficial capillaries in the nerve fiber bundles near the optic disc. These capillaries originate directly from arterioles so that when autoregulation fails, the high systemic pressure is transmitted directly to the capillaries. This process leads to breaks in the continuity of the capillary endothelium. The resultant hemorrhages extend along nerve fiber bundles parallel to the retinal surface. The hemorrhages often have a frayed distal border owing to extravasation of blood between nerve fiber bundles.

Cotton-wool spots are the most characteristic feature of malignant hypertension. They usually surround the optic disc and most commonly occur within three disc-diameters of the optic disc. Cotton-wool spots result from ischemic infarction of retinal nerve fiber bundles owing to

Vitreous Retina Unit
Sir Ganga Ram Hospital
New Delhi

Table 1: Differential diagnoses for cotton wool spots

<i>COMMON</i>	<i>LESS COMMON</i>
Diabetes	Cardiac valvular disease
Hypertension	Carotid artery obstruction
Retinal arteriole occlusion	Hematologic abnormalities: Anemia, Leukemia,
Retinal vein occlusion	Thrombocytopenia, Thrombocytosis
Collagen-vascular diseases	Purtscher's retinopathy
AIDS retinopathy	Lymphoma

arteriolar occlusion.. In order for cotton wool spots to develop from hypertension, autoregulatory mechanisms must first be overcome. For this to happen, the patient must have at least 110mmHg diastolic readings.

Cotton-wool spots tend to distribute around the optic disc because nerve fiber bundles are most dense in this region. The detection of cotton-wool spots is a crucial clinical finding because they are the retinal manifestation of the malignant hypertension- systemic vasculopathy that also causes ischemia in the kidney and other organs.

Patients who develop disc oedema from hypertension have malignant hypertension and typically have BP in the range near 250/150mmHg. The major mechanisms for optic disc edema in hypertension include the following:

- ♦ Increased intracranial pressure and hypertensive encephalopathy.
- ♦ Loss of autoregulation of optic nerve head blood flow and disc edema.
- ♦ Hypertensive retinopathy and choroidopathy with secondary optic neuropathy due to ischemia.

Initial Investigations

The evaluation should proceed in a stepwise fashion. The vitals should be measured first. All patients with bilateral disc oedema should have their BP measured at initial examination. If the BP is normal then an underlying vascular process might be suspected because of the nerve fibre layer infarcts (cotton wool spots). The finding of even

a single cotton wool spot in a patient without known vascular conditions, necessitates further evaluation. We should start with a review of systems aimed at uncovering rheumatological and vascular disorders. The blood tests would include a complete haemogram including a platelet count, ESR, CRP, blood sugar, HIV testing, antinuclear antibody and ANCA. Other considerations would include Behcet's disease and sarcoidosis.

Management of the case

Hypertension may be unknown to the patient and the eye exam may yield the first clue to this relative asymptomatic systemic disease. Management of hypertensive retinopathy involves appropriate treatment of the underlying hypertension. If a patient presents with disc oedema due to hypertension, then the patient has malignant hypertension and should be considered to be in a medical crisis. This patient needs immediate consult with a physician and, most likely, immediate transport to a hospital emergency room.

The roles of the ophthalmologist are to:

- ♦ Be aware of hypertension as a cause of disc edema.
- ♦ Check the blood pressure in patients with papilledema.
- ♦ Avoid too rapid a reduction of blood pressure, which can lead to inadvertent cerebral and optic nerve ischemia.

Arteriolosclerotic changes in the retinal microvasculature persist even with the reduction of systemic blood pressure. However, hypertensive retinopathy changes resolve over time with the reduction of systemic blood pressure. Cotton wool spots develop in 24 to 48 hours with the elevation of BP, and resolve in two to 10 weeks with the lowering of BP. A macular star develops within several weeks of the development of elevated BP and resolves within months to years after the BP is reduced. Papilledema develops within days to weeks of increased BP and resolves within weeks to months following BP lowering.

!! Attention DOS Members !!

The last date of acceptance of application for DOS Fellowship for partial assistance to attend conference has been extended to ***30th October instead of 30th September, 2005*** for **National Conference (AIO 2006)**.

Proliferative Diabetic Retinopathy - Challenges & Tips

Lalit Verma, MD, Dinesh Talwar, MD

Diabetes mellitus is a huge problem in our country. Thanks to life style problems (stress, lack of exercise, dietary indiscretion, excessive alcohol etc) and abdominal obesity (38 % Indians suffer from abdominal obesity), India has the largest number of diabetics in any single country. 12.5 % of India's urban population & 4 % of the rural population is dioptic. Diabetes is the mother of all diseases since it affects all the parts of the body.

A previous issue of DOS times carried a well illustrated article on the 'Role of Fluorescein Angiography in Diabetic Retinopathy'. This article shall try to discuss the management of Proliferative diabetic Retinopathy, which has the potential to make the patient blind, that too irreversibly.

Detailed clinical examination & Fluorescein Angiography helps you to differentiate between proliferative & non-proliferative retinopathy. Besides making the job quicker FFA helps in picking up :

- ♦ CNP areas, (Fig. 1)
- ♦ Invisible NVE's
- ♦ Areas of associated macular leak (remember that diagnosis of maculopathy & CSME is based on slit-lamp biomicroscopy),
- ♦ Type of macular leak (focal / diffuse -which have different pathophysiology different management & different prognosis)
- ♦ Diagnosis of ischemic maculopathy-difficult condition to manage, has poor prognosis
- ♦ Follow-up & evaluation of treatment

The classic and established indication of laser treatment in proliferative retinopathy is the presence of neovascularisation with high risk characteristics. There are some special situations when laser treatment may be considered in patients with mild PDR and severe NPDR. These situations include: severe NPDR in both eyes (one eye of such patients can be considered for scatter laser), one-eyed patient with severe NPDR- other eye lost because of complications of PDR, pregnant ladies with severe NPDR, diabetics with severe NPDR likely to undergo cataract surgery in near future. All these situations become more

significant if patient is unlikely to follow-up regularly and angiography shows significant areas of capillary non-perfusion and leakage. (Chart 1, Fig. 1)

If patient fits into the criteria of PDR with HRC (Fig. 2a-b), he should be subjected to Full-Scatter laser photocoagulation. (Mild Scatter, previously called posterior pole scatter, is generally not used & is practically out dated because with it, there is higher risk of development of PDR with HRC & there is no decrease in the incidence of moderate or severe visual loss.) There should be a sense of urgency involved in doing full scatter, since if untreated or delayed, vitreous hemorrhage & its attendant complications may ensue & despite successful vitreous surgery things are never going to be the same as they could have been.

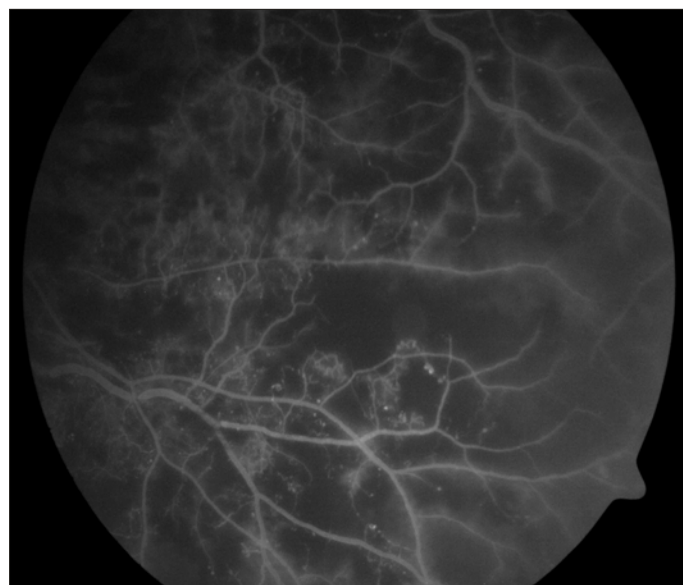
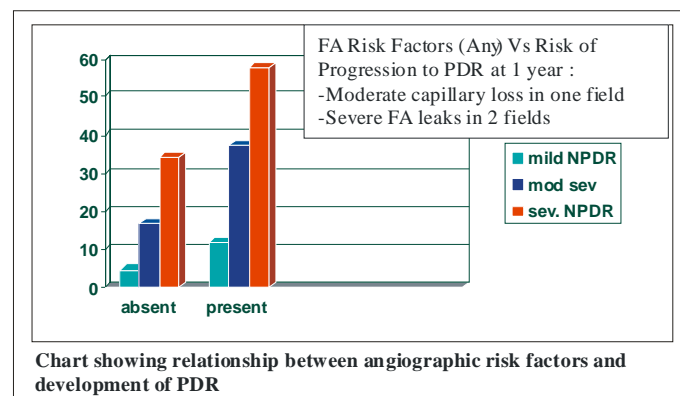


Fig.1: Angiogram showing extensive CNP areas

Senior Consultants, Vitreo-Retina Service
 Indraprastha Apollo Hospitals & Centre for Sight,
 New Delhi

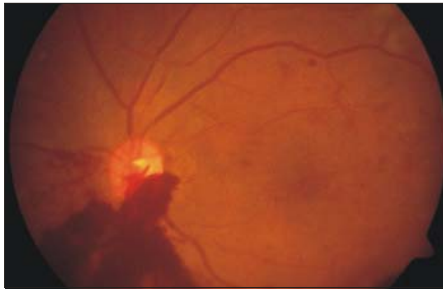


Fig.2a : Patient of PDR with HRC (Vision is 6/6)

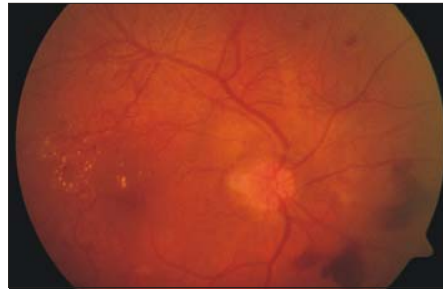


Fig. 2b: Large neovascular area in the superior retina

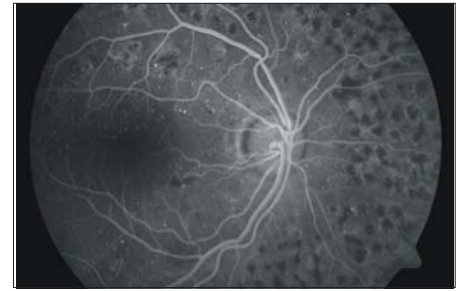


Fig.3: Ideal full scatter laser

An ideal full scatter treatment (Fig. 3) should involve 3-4 sittings with patient counseled with the help of live colored fundus photographs and angiograms (preferably on a digital system, because it allows vertical comparisons instantaneously)

We use 200-300 u spot size, duration of 100-150 msec and power adjusted to give a moderate intensity burn (Table). Equidistant spots should be placed nicely in a linear fashion along the vessels (avoid retinal vessels as far as possible). Haphazardly placed spots make re-treatments or fill-in treatments (if & when required) very difficult.

General rule is to treat the inferior quadrant first (since if by any chance vitreous bleed occurs-this can, by settling inferiorly & obscuring the visualization of the inferior retina hinder in the proper placement of burns)

The initial limits of scatter laser are:

Posteriorly : Superiorly & Inferiorly - temporal vascular arcades

Nasally - $\frac{1}{2}$ DD from disc

Temporally - 2 DD from foveal center

Anteriorly : Equator (recognized by ampulla of vortex veins)

The initial burn is a burn of moderate intensity (Gr 2/3) which is ensured by increasing the power gradually. If this does not work, can decrease the spot size to 100 u. If this also does not work, one should increase the duration to 0.15-0.2 sec.

In eyes with clear media, one should try not to increase the duration of burn beyond 0.2 sec-since this results in

exponential increase in patient's discomfort. In eyes with hazy media (eg. Resolving vitreous hemorrhage / cataract), you can increase the burn duration or even use continuous wave. Even if 200-300 burns are placed, clearance of vitreous hemorrhage generally starts (ARC type effect).

If macular treatment is also warranted, this should be done (focal / grid / both) in the first sitting itself.

Number of sittings & Number of spots: although there is no hard and fast rule, scatter laser is generally done in 3-5 sittings and in each sitting (spaced 3-7 days apart), one should avoid giving more than 800-1000 spots of 200 u. Excessive laser, besides causing pain and discomfort, can cause choroidal effusion specially if excessive energy is used. (Fig. 4a, 4b)

Generally the laser used for scatter laser is Argon green (514 nm) or more commonly the solid state frequency-doubled Nd-YAG laser (532

Table: Laser Technique in DR		
<i>Burn characteristics</i>	<i>Classic</i>	<i>Personal preference</i>
♦ Spot Size	500 μ	200 μ
♦ Exposure	0.1 sec	0.1 sec.
♦ Intensity of burns	Moderate	Gr III or Gr II reaction (moderate)
♦ No. of burns	1200-1600	3500-4500 (Approx)
♦ No. of episodes	> 2	> 3
♦ Follow up	4 months later	3 months later

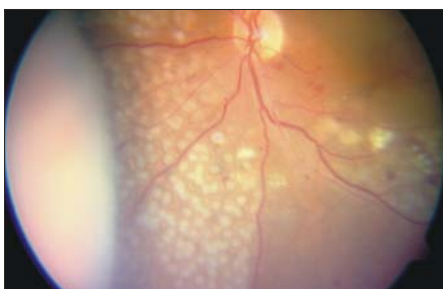

Fig. 4a: Choroidal effusion after scatter laser-generally caused by large number of heavy burns in a single sitting.

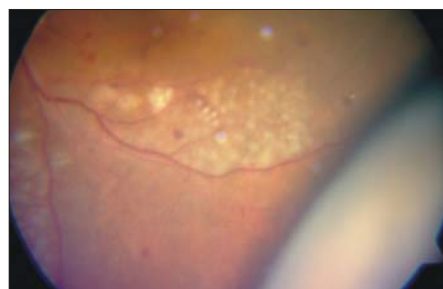

Fig. 4b: Other eye of same patient, as in Fig. 4a, also developed choroidal effusion after laser

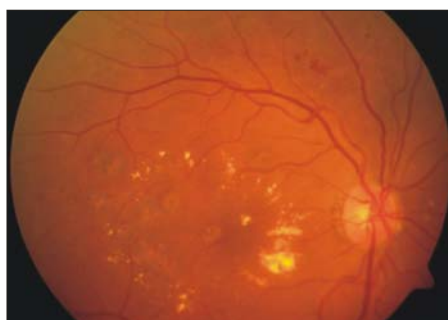


Fig. 5a: Color photo of a patient with maculopathy

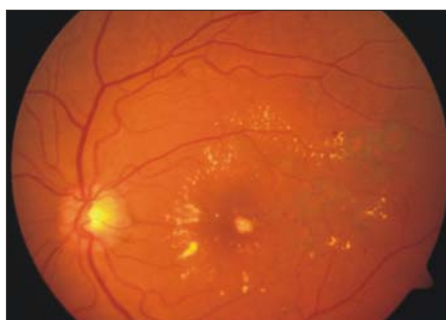


Fig. 5b: Fellow eye of same patient, as in Fig. 5a

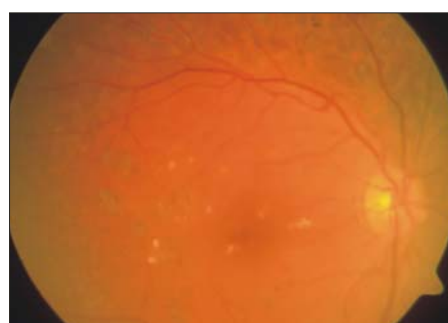


Fig. 5c: Color photo of same patient, as in Fig. 5a, after laser treatment

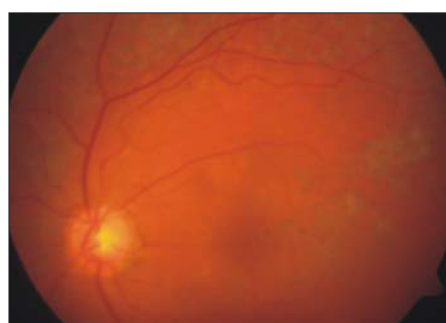


Fig. 5d: Left eye of same patient, after laser treatment (Pre-laser-photo Fig. 5b)

nm). Blue-green laser is obsolete out because 488 nm wavelength is harmful to macula; more over blue-green laser is difficult to maintain. Diode laser (810 nm) is a macula-friendly laser but causes intense pain if used for doing scatter laser, since large number of spots have to be given. Further it is very difficult to do a complete job involving full scatter laser with a diode laser. Sub-threshold laser is a good concept to minimize the destructive effect of a visible burn, specially when you are treating the macular area-but it is not easy (to place the spot without seeing) and requires experience.

Contact lens used for facilitating scatter laser is generally a Volk quadrispheric (or any equivalent moderate field visualization lens-like Mainster/transequator) which provide a panoramic view of the

fundus. They are used with a coupling fluid like Goniosol or any other 2% methyl cellulose solution. One should avoid using lignocaine, since it's coupling action is less & it can cause corneal haze. Use of Goldman three mirror lens for scatter laser is also not recommended, specially for the beginners, since field of view provided at a time is limited and inadvertent macular laser is possible.

After completion of scatter laser, patient is put on topical non-steroidal anti-inflammatory drops for couple of weeks. There are some patient - related factors which the patient is asked to pay attention to. These include: maintenance of ideal / close to ideal body weight & BMI, good glycemic control, control of associated hypertension & avoidance of smoking. Serum lipid profile if deranged needs to be corrected in consultation with a cardiologist. If the renal parameters (blood urea, serum

creatinine & 24 hr urinary protein) are significantly raised, patient should preferably be dialysed prior to laser treatment.

Post laser, although patient may be seen at 2 weeks and 4 weeks (to see for any untoward complications), but assessment of laser treatment is generally done 2-3 months after the completion of scatter laser. This assessment could be clinical, supplemented sometimes by angiography. Clinically, signs of a good successful laser include (Fig. 5a-d): reduced number of exudates and hemorrhages, stabilization / sometimes improvement of visual acuity, reduction in the angry look of NVD / NVE, appearance of fibrous component in the areas of previous new vessels, reduced caliber of retinal vessels. On angiography (Fig. 6a-f), regression of NVD & NVE may be seen. Presence of NVD

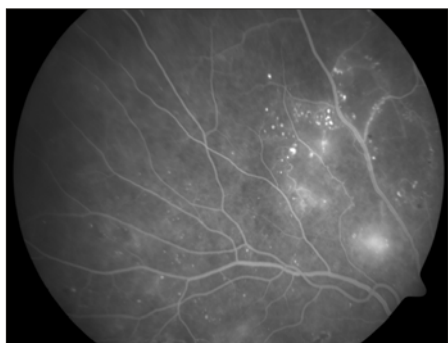


Fig. 6a: FFA of same patient as in Fig. 5a, before laser

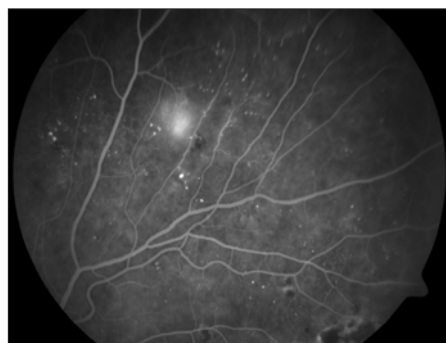

Fig. 6b: FFA of same patient as in Fig. 5b, before laser

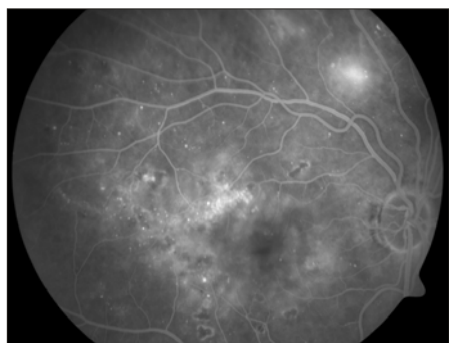


Fig. 6c: FFA of same patient as in Fig. 5a, late phase, before laser

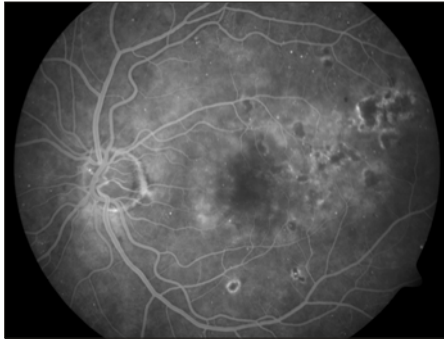


Fig. 6d: FFA of same patient as in Fig. 5b, late phase, before laser

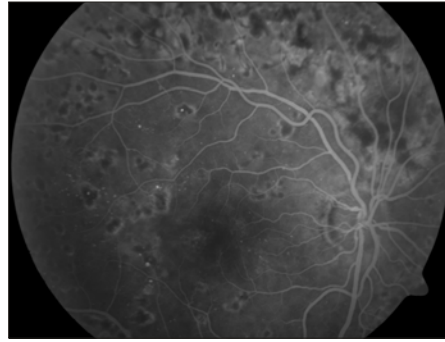


Fig. 6e: FFA of same patient as in Figs 5a, 5c, 6a, 6c

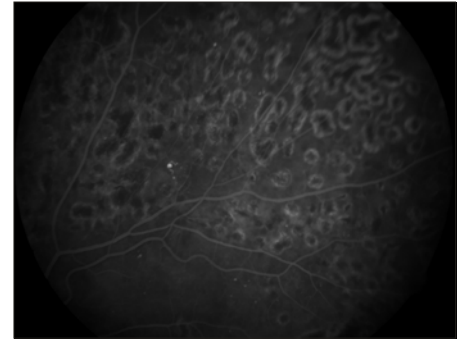


Fig. 6f: FFA of same patient as in Figs 5b, 5d, 6b, 6d

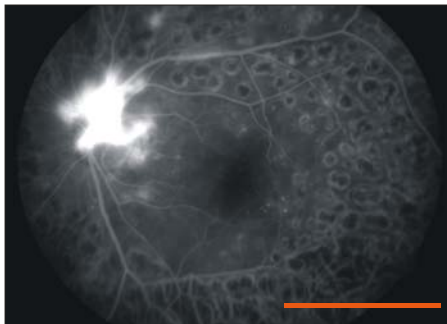


Fig. 7: Leak from NVD in an otherwise well-lasered DR patient. NVD is becoming fibrotic with minimal vascular component

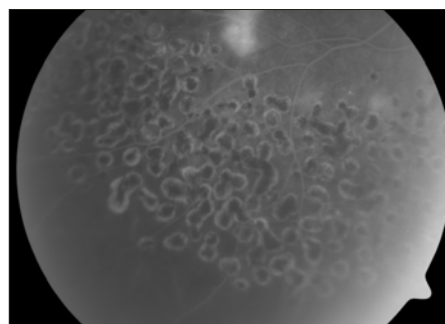


Fig. 8: Angiogram showing inadequate laser. Note presence of NVE and CNP areas

or mild leak from previous large NVD in an otherwise well-done scatter laser does not necessarily indicate need for re-treatment. (Fig. 7)

If patient has already been lasered before & still shows active neovascularisation (clinically & on FFA - Fig. 8):

- ♦ See for skip areas / gaps and fill-in laser in these areas
- ♦ Treat neovascular area(s) directly-if in safe area (away from disc & macula)
- ♦ Can try direct laser of feeder arteriole if identifiable (never the venule, because can result in hemorrhage)- but this should be done after completion of scatter laser in that quadrant.
- ♦ This may sometimes require careful use of long duration burns or even continuous wave burn. (Please remember to lower the power if & when duration is increased)
- ♦ Extend laser anterior to equator (sply in eyes with HRC/ extensive proliferative disease) by LIO

Not infrequently the patient presents with vitreous hemorrhage.

If the hemorrhage is dense & obscures visualization with indirect ophthalmoscope-policy is to do a dynamic & quantitative B-scan and assess the vitreo-retinal relationship.

If there is no RD (generally tractional, sometimes combined tractional + rhegmatogenous) & hemorrhage is recent:

Patient is asked to be propped up (not strictly confined to bed) & given topical cycloplegics & non-steroidal anti-inflammatory agents and reviewed after 5-7 days. Propping up aids in gravitational settling of blood- this may help to initiate scatter laser by LIO in the upper part of retina - which further helps in somewhat

faster resolution of hemorrhage. Personal experience tells that a lot of eyes are saved from vitrectomy by following this regimen.

If, however, there are no signs of clearing, (generally assessed by dilated pupil indirect ophthalmoscopy & looking for increased visualization of the superior retina) within 1-2 weeks, we repeat USG (look for PVD/localized tenting of retina/extensive RD/ large fronds etc) & if there is no RD (specially macular TRD), patient can be further observed for 2-3 weeks, specially if the fellow eye has good vision. However the role of positioning now decreases.

If after complete scatter laser & maximal augmentation, response is still inadequate or if re-bleeding occurs, one should actively consider vitreous surgery. (It is generally observed that in patients in whom vitreous hemorrhage does not reabsorb, they have strong, persistent vitreo-retinal attachments to the proliferating tissue-generally involving the vascular arcades, optic nerve or the whole posterior pole). Infact, with refinements in instrumentation, better quality vitrectomy machines, increasing experience, surgeons now enter the vitreous cavity much earlier (it is not mandatory to wait for the classic teaching of 6 months)-generally within 2 months of non-resolving, uncomplicated vitreous hemorrhage. However if hemorrhage is complicated by presence of RD or macular traction, one should do the more definitive vitreous surgery as early as possible-even at first

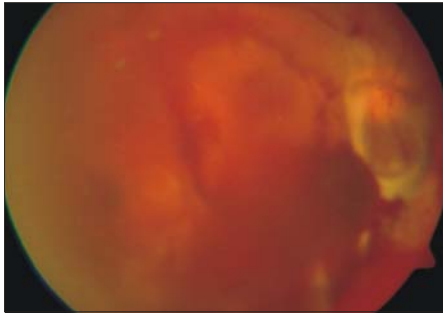


Fig.9a: Florid PDR with large pre-retinal hemorrhage

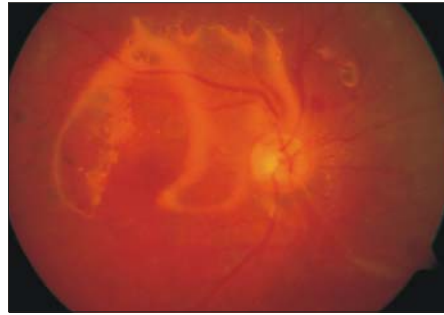


Fig.9b: Same patient as in Fig. 9a, after vitreous surgery – Note silicone oil reflexes

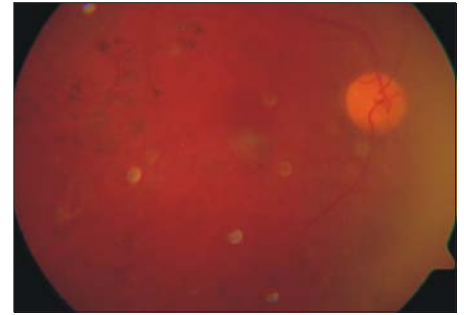


Fig.9c: Same patient as in Fig. 9b, after removal of silicone oil

presentation. (Fig. 9a-c)

Diabetic vitrectomies are generally the toughest & most time consuming of all vitreous surgeries (Stage V ROP may be tougher)-more challenging than Eales' vitrectomy or PVR surgery. Combined cataract and vitreous surgeries are becoming more frequent. Posterior vitreous detachment is generally absent or incomplete. Delamination and Segmentation are preferred over peeling techniques. You cannot do without intravitreal scissors (curved, horizontal and vertical scissors), intravitreal diathermy, brush needle and endolaser. Bimanual manipulation of fibrovascular vitreo-retinal tissue (using 4-port vitrectomy or combined instrumentation) may be required to minimise damage to retina.

All the above factors make the surgery more challenging and expensive & should be discussed with the patient and relatives

The results of diabetic vitreous surgery are best in a metabolically controlled patient who has been previously lasered.

Intravitreal Steroids in Retinal Disorders

Mohita Sharma M.S., Angshuman Goswami M.S., D.N.B.,
Ruchi Rai M.S., D.N.B.

The unwanted proliferation of intraocular tissue is one of the important problems, largely unsolved, in clinical ophthalmology. Corticosteroids have long been known to reduce inflammation in many ocular diseases, given either locally or systemically. Often, however, the intraocular concentration of cortisone was not high enough, or the systemic side effects were too pronounced. Machemer, Peyman and other researchers studied the possibility of injecting cortisone directly into the eye, in experimental settings in animals as well as in selected clinical situations in patients (1, 2). They found that the cortisone may not be toxic to the intraocular tissue. It agrees with clinical observations of eyes into which cortisone accidentally was injected as well as with recent clinical and experimental studies on the therapeutic effect of intravitreal triamcinolone acetonide (IVTA) or other steroids, given either as an intravitreal injection of crystals or applied as intravitreal implants release devices, for various intraocular edematous, neovascular, inflammatory or proliferative diseases (3, 4, 5).

Uses

Corticosteroids are currently being used in retinal disorders in mainly two forms:

1. Intravitreal triamcinolone acetonide which has become an increasingly popular method to treat macular disease amongst vitreoretinal surgeons. While data from randomized controlled clinical trials are lacking, IVTA has quickly found widespread application for a variety of posterior segment pathologies.
2. Intravitreal slow release devices or implants

1. Macular edema

IVTA has been used to treat macular edema of various etiologies including:

a. Diabetic macular edema (DME)

Intravitreal triamcinolone improves vision in eyes with chronic diabetic macular edema refractory to laser

photocoagulation. Fluorescein angiographic and OCT studies have proved the role of IVTA in such cases. It has also been advocated for primary usage in some cases. There have been studies where after where eyes which were refractory to laser photocoagulation were subjected to IVTA injection which reduced the retinal thickness at the macula. This was followed by grid photocoagulation.

Intravitreal triamcinolone acetonide was first proposed in 1999 as a treatment for diabetic macular edema because of the safety profile demonstrated in animal models, prior clinical experience with other retinal diseases, and the rationale of attenuating the VEGF-mediated retinal capillary permeability that is presumed to contribute to diabetic macular edema. The use of intravitreal triamcinolone acetonide is now widespread among ophthalmologists. Rapid and dramatic resolution of refractory diabetic macular edema and improvement in visual acuity has been seen after intravitreal triamcinolone injection. Furthermore, the treatment is inexpensive and readily available.

Martidis et al. (6) reported results using intravitreal triamcinolone acetonide injection in 16 eyes with macular edema due to diabetic retinopathy. All 16 eyes had persistent macular edema after having received multiple sessions of laser photocoagulation. Using optical coherence tomography, it was demonstrated that the mean thickness of the central macula decreased from 540 μ m before injection (at baseline) to 242 μ m after injection (the normal average thickness of the central macula is 175 μ m). Visual acuity improved from the baseline values.

Jonas et al. (7) described the results of intravitreal triamcinolone acetonide injection in 26 eyes with macular edema due to diabetic retinopathy. All 26 eyes had visual acuity loss due to diabetic macular edema for at least 1 year. The mean follow-up time was 6.6 months. For the 21 patients in whom both the pre and post injection fluorescein angiogram was available, evaluation showed decreased fluorescein leakage following intravitreal injection in all patients. Visual acuity improved in the triamcinolone group. In comparison, 16 patients followed in a control group who received laser photocoagulation showed no improvement in visual acuity.

b. Macular edema from central retinal vein occlusion (CRVO) and branch retinal vein occlusion (BRVO)

Intravitreal triamcinolone has also been tried for the treatment of CRVO and BRVO in patients with cystoid

Tirupati Eye Centre

C-8, Sector 19,
Noida, Ghaziabad (U.P.)

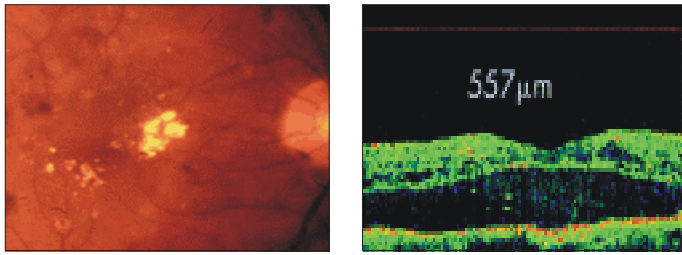


Fig 1: Fundus photograph of a case of diabetic macular edema with hard exudates. OCT shows a macular thickness of 557 microns

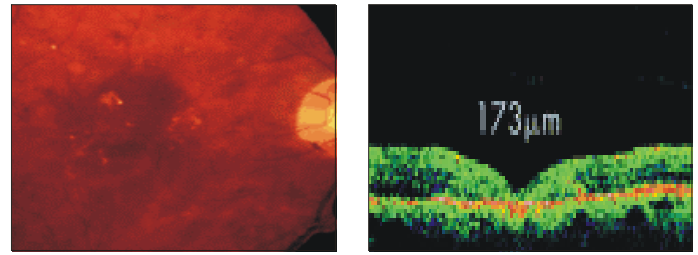


Fig.2: Fundus photograph of the same case as in figure 1 6 months after IVTA injection showing resorption of hard exudates. OCT shows a macular thickness of 173 microns

macular edema and worsening vision(8). Studies have shown that majority of patients have had reduction in edema with some visual improvement, while some had no benefit. Visual gain is poor following IVTA injection in cases of CRVO with macular edema despite the decrease in edema after the injection on account of ischemic changes that have already been induced by the vascular occlusion

- c. *Pseudophakic cystoid macular edema (Irvine-Gass syndrome)*
- d. *Idiopathic cystoid macular edema*

2. Wet age-related macular degeneration

Ocular photodynamic therapy with verteporfin has been demonstrated to reduce visual loss in patients with predominantly classic type of exudative age related macular degeneration. For the predominantly occult type and the minimally classic type of age related macular degeneration, however, none of the currently available treatments have been shown to be markedly effective in reducing the loss of vision. Studies have shown that the intravitreal triamcinolone acetonide in combination with verteporfin photodynamic therapy may be useful to stabilize or temporarily improve visual acuity in such patients. It has been seen that combined therapy could reduce the need for PDT re-treatment in eyes with exudative AMD. Triamcinolone is considered to be relatively inexpensive. For patients who are having PDT performed to treat AMD, the need for re-treatment as well as the need for more frequent fluorescein angiography adds significantly to the cost, so the use of triamcinolone could reduce the cost of the procedure significantly, while at the same time adding some measure of protection to whatever visual acuity the patient might have left (9).

3. Uvietis

High doses of upto 25 mg have been used for long in cases of uvietis.

4. Surgical adjunct

Intravitreal triamcinolone is being used as a surgical adjunct for perioperative control of ocular inflammation

and intraoperative identification of vitreoretinal tissue planes (posterior hyaloid and epiretinal membranes). IVTA crystals injected after vitrectomy coat the residual vitreous thus helping in removing of residual vitreous during vitrectomy.

Technique of injection

The intravitreal injection of triamcinolone acetonide should be performed under sterile conditions in the operating theatre using an operating microscope and topical anesthesia. Some surgeons prefer to perform a paralimbal paracentesis to reduce the intraocular volume though most do not recommend it nowadays. 1- 25 mg triamcinolone acetonide (available commercially as Kenalog/Kenacort) is injected transconjunctivally at a distance of 3-3.5 mm from the limbus (Figure 3). The injection can be made with a 26, 27 or 30 degrees needle mounted on a tuberculin syringe under direct visualization. After inserting the needle through the pars plana, when the needle tip became visible, the tip is turned to point the bevel posteriorly and the steroid injected very slowly into the mid-posterior vitreous cavity. IVTA crystals become visible immediately after the injection in vitreous cavity as white chalky particles (Figure 4). Eye should be examined immediately afterwards for the presence of central retinal artery (CRA) pulsations and those with impending obstruction can undergo a paracentesis. All eyes should be re-examined at 15 min to half an hour after the injection to measure the IOP and any immediate post injection complications. Patients should be prescribed antibiotic eye drops for at least 3 weeks. The white chalky drug may be visible like a cat's eye reflex taken on nighttime photographic film. This generally lasts only for about three weeks.

Since there are several controversies on the correct method of injection, in mid 2004 a panel of ophthalmologists at Bascom Palmer eye institute, University of Miami has set certain guidelines for the correct technique especially in view of the increasing popularity of intravitreal triamcinolone (10).

The panelists developed a set of guidelines, some of which had consensus agreement, such as:

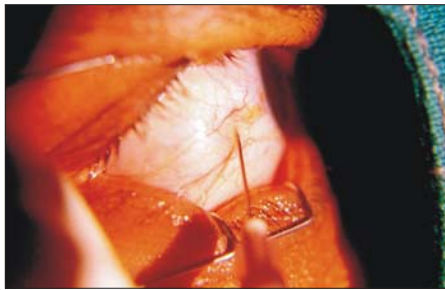


Fig. 3: Intravitreal triamcinolone injected 3.5 mm from the limbus

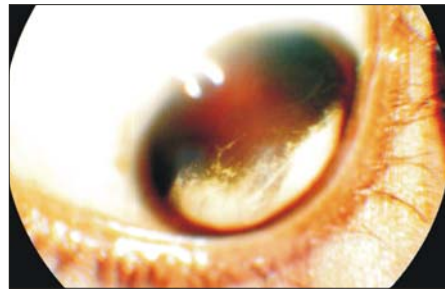


Fig. 4: White chalky crystals of triamcinolone visible in the vitreous cavity immediately following IVTA injection

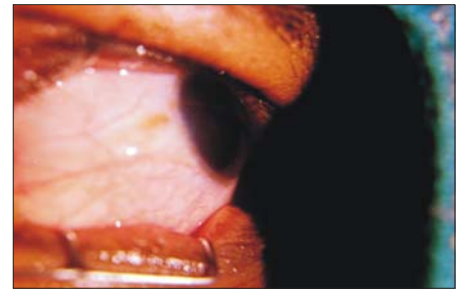

Fig. 5: Application of povidone iodine on conjunctiva, lid margins and lashes and use of lid speculum decreases chances of infection

1. Use of povidone-iodine and lid speculum (Figure 5)
2. Avoidance of extensive massage of the eyelids
3. Avoidance of injecting patients with active eyelid or ocular adnexal infection
4. Dilatation of the pupil in order to view the posterior segment immediately after injection
5. Use of adequate anesthesia and
6. Avoidance of prophylactic or post-injection anterior chamber paracentesis.

There were some factors on which there was less agreement. Most of the panelists did not use a sterile drape, most advocated the use of gloves, there was no agreement on the use of pre- or post-injection topical antibiotics, no agreement on specific intraocular pressure levels at which the physicians are comfortable discharging the patient, and disagreement on when to see the patient back for follow-up after injection.

Dosage and preparations

Dosages varying from 1 mg to 25 mg have been used as intravitreal injections of triamcinolone. Nowadays lower doses of 1 and 4 mg are being advocated to decrease the incidence of side effects. Duration of the effect of an intravitreal application of triamcinolone acetonide lasts between 4 weeks to 9 months (average 6 months). Significant improvement in visual acuity has been seen in the triamcinolone-treated patients, which is obvious at 6 weeks, and is maintained to some extent for 6 months, but drops to pretreatment levels by 7 months (7).

The data of one study suggests that the repeated intravitreal injection of about 20 mg of triamcinolone acetonide as treatment of diffuse diabetic macular edema can be associated with a increase in visual acuity again in those patients who as "triamcinolone responders" showed

an improvement in visual acuity after a preceding intravitreal injection of triamcinolone acetonide (11). One of the main highlight in this matter is that since many intravitreal injections are required, higher doses of triamcinolone should preferably be avoided.

Till recently Kenalog or Kenacort was the preparation that was commercially available for intravitreal use. There are, however, concerns about the toxicity of the preservative used in this commercially available preparation. Sterile endophthalmitis has been reported following IVTA injection. Removal of benzyl alcohol has been suggested as a way of decreasing side effects associated with triamcinolone.

'Preservative-free intravitreal triamcinolone is now available. In a pilot series of 10 patients this formulation has shown a good safety profile. No patient had any adverse effects. There was a statistically significant reduction in macular thickness on OCT. Another study with the preservative free triamcinolone used to treat macular edema in 10 eyes of 10 patients in a 4 mg dosage has shown that this formulation appears to disperse more in the vitreous rather than to clump as was the tendency with the standard preparation of Kenalog.

In another study, the pharmacy prepared the solution free of solvent agents or other vehicles, to generally prevent any potentially toxic effect of a vehicle to intraocular tissues. 25 mg of triamcinolone acetonide was taken, diluted in Ringer's solution, and pressed through a Millipore filter, the whole procedure was repeated three times, finally resulting in a solution of 0.2 ml containing 25 mg of triamcinolone acetonide crystals. No cases of endophthalmitis were reported in this study (9).

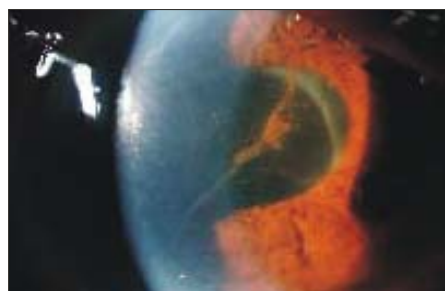


Fig.6: Infectious endophthalmitis following intravitreal triamcinolone injection. Fibrin is seen in the anterior chamber. Staph. Epidermidis was isolated from the vitreous tap

Complications

Several injection-related and drug-related complications have been identified. Localized subconjunctival

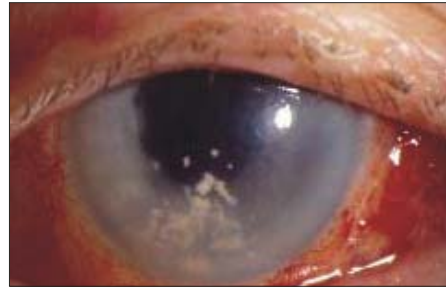
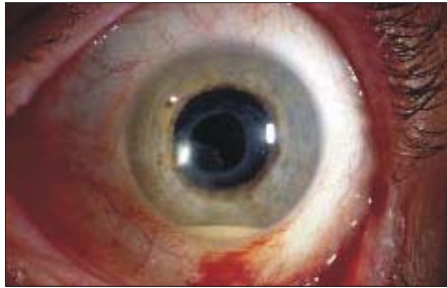
Fig. 7 & 8: Sterile endophthalmitis after IVTA injection

hemorrhage is a common finding following IVTA injection. Potential serious injection-related complications include acute traumatic cataract, retinal detachment due to increased vitreous traction or direct needle perforation of the retina and vitreous hemorrhage. Corticosteroid-induced ocular hypertension, glaucoma, and cataract have been described. Infectious endophthalmitis has been reported, but more commonly encountered are the findings of non-infectious endophthalmitis.

Mild to moderate intraocular pressure elevation was seen in patients, typically in the first three months following IVTA injection. This was usually well-controlled with topical antiglaucoma agents. A known history of open-angle glaucoma does not appear to increase the risk of IVTA-induced ocular hypertension (12, 13). Although most reports of IVTA-induced ocular hypertension have demonstrated a good response to topical antiglaucoma therapy alone, recent studies have reported "intractable" cases. In one study, one patient required glaucoma filtration surgery and vitrectomy (14).

Infectious endophthalmitis has been reported in three studies (10, 15, and 16). These studies have reported an incidence varying from 0.5 to 0.9% (Figure 6). This has prompted greater awareness for the need of a sterile procedure, emphasizing the use of povidone-iodine preparation and lid speculum.

Several studies have described non-infectious endophthalmitis after IVTA. In one study, one of 16 patients (6.3 percent) developed a "whitish" pseudohypopyon without pain or other signs of ocular inflammation (17). Pseudohypopyon (triamcinolone crystals in anterior chamber) was described in seven of 828 patients (0.8 percent) within three days of receiving an IVTA injection (18). All experienced complete resolution within two weeks. Clinical examples of a pseudohypopyon can be seen in Figures 7 and 8.

With respect to other complications of the intravitreal injection of triamcinolone acetonide, cortisone crystals have not been found

to settle on the macular region. The crystals were preretinally located in the vitreous cortex at the 6 o'clock position and do not interfere optically with vision. Additionally, a toxic effect of triamcinolone acetonide crystals lying on the macula has not been shown.

Intravitreal slow release devices (Implants)

The Envision TD implant (Retisert) (Figure 9) is a slow release device which is similar to the ganciclovir implant being called Vitrasert which is a FDA approved implant being used for CMV retinitis. The Envision TD implant contains steroid Fluocinolone in it. It has a strut which is secured to the sclera. The strut has a pellet attached to it which contains Fluocinolone within it. A 5.5 mm scleral incision is made at the pars plana. Any prolapsed vitreous is removed with the vitrector and the implant is anchored to the sclera and the sclerotomy closed with nonabsorbable suture. The steroid is released slowly over a period of 3 years from the pellet into the vitreous cavity. The FDA approval for this implant is awaited.

Future

Intravitreal triamcinolone is a promising therapy for several retinal disorders. Though several studies have been published which have shown a definitive role of this therapy, randomized case controlled multicentric studies are required to prove its role conclusively. More research is required especially with the preservative free intravitreal triamcinolone injection.

References

1. Machemer R Sugita G, Tano Y. Treatment of intraocular proliferations with intravitreal steroids. *Trans Am Ophthalmol Soc* 1979; 77:171-80.
2. Tano Y, Chandler D, Machemer R. Treatment of intraocular proliferation with intravitreal injection of triamcinolone acetonide. *Am J Ophthalmol* 1980; 90:810-16
3. Jonas JB, Kreissig I, Degenring R. Intraocular pressure after intravitreal injection of triamcinolone acetonide. *Br J Ophthalmol* 2002; 86:1450-1.
4. Danis RP, Ciulla TA, Pratt LM, et al. Intravitreal triamcinolone acetonide in exudative age-related macular degeneration. *Retina* 2000; 20:244-50.
5. Penfold PL, Wong JG, Gyory J, et al. Effects of triamcinolone acetonide on microglial morphology and quantitative expression of MHC-II in exudative age-related macular degeneration. *Clin Exp Ophthalmol*




Fig. 9: Intravitreal Fluocinolone implant

- 2001; 29:188-92.
6. Martidis A, Duker JS, Greenberg PB, Rogers AH, Puliafito CA, Reichel E, Bauman C: Intravitreal triamcinolone for refractory diabetic macular edema. *Ophthalmology* 109:920-927, 2002
 7. Jonas J, Kreissig I, Sotker A, Degenring R: Intravitreal injection of triamcinolone for diffuse diabetic macular edema. *Arch Ophthalmol* 121:57-61, 2003
 8. Ip MS, Kumar KS. Intravitreal triamcinolone acetonide as treatment for macular edema from central retinal vein occlusion. *Arch Ophthalmol* 2002; 120:1217-1219.
 9. Jonas JB, Kreissig I, Hugger P, Sauder G, and Panda S: Intravitreal triamcinolone acetonide for exudative age related macular degeneration. *Br J Ophthalmol* 2003; 87:462-468.
 10. Aiello LP, Brucker AJ, Chang S, Cunningham ET Jr, et al. Evolving guidelines for intravitreal injections. *Retina* 2004; 24:S3-S19.
 11. JB Jonas, I Kreissig, R F Degenring and B A Kampeter Repeated intravitreal injection of triamcinolone acetonide for diffuse diabetic macular edema *British Journal of Ophthalmology* 2005; 89:122
 12. Gillies MC, Simpson JM, Billson FA, et al. Safety of an intravitreal injection of triamcinolone: results from a randomized clinical trial. *Arch Ophthalmol* 2004;
 13. Bakri SJ, Beer PM. The effect of intravitreal triamcinolone acetonide on intraocular pressure. *Ophthalmic Surg Lasers Imaging* 2003; 34(5):386-90.
 14. Singh IP, Ahmad SI, Yeh D, et al. Early rapid rise in intraocular pressure after intravitreal triamcinolone acetonide injection. *Am J Ophthalmol* 2004; 138(2):286-7
 15. Nelson ML, Tennant MT, Sivalingam A, et al. Infectious and presumed noninfectious endophthalmitis after intravitreal triamcinolone acetonide injection. *Ref* 2003; 23(5):686-91.
 16. Benz Mycobacterium chelonae abscesses after intravitreal injection of triamcinolone. *Arch Ophthalmol* 2003; 121(2):271-3.
 17. Jonas JB, Hayler JK, Panda-Jonas S. Intravitreal injection of crystalline cortisone as adjunctive treatment of proliferative vitreoretinopathy. *Br J Ophthalmol* 2000; 84(9): 1 064-7.
 18. Moshfeghi AA, Scott ill, Flynn HW Jr., Puliafito CA. Pseudohypopyon after intravitreal triamcinolone acetonide injection for cystoid macular edema. *Am J Ophthalmol* 2004; 138(3):489-92

Editor Note: The Ministry is now providing aid & grants for those desirous of setting up an Eye Bank. These are some guidelines provided.

National Programme for Control of Blindness Schemes for Participation of Voluntary Organisations Revised

Govt. of India Ophthalmology/Blindness Control Section
Directorate General of Health Services
Ministry of Health and Family Welfare
Nirman Bhawan, New Delhi-110 01

I. Non-recurring grant-in-aid for setting up/strengthening of Eye Banks and Eye Donation Centres

Objective

To promote Eye Banking activity in the country through Government facilities, NGOs and other stakeholders to get adequate tissue for corneal transplantation for treatment of corneal blindness.

Eye Donation Centre (EDC)

Eye Donation Centre is affiliated to a registered Eye Bank, which should provide:

- i. Public and professional awareness on eye donation;
- ii. Co-ordinate with donor families and hospitals to motivate eye donation;
- iii. Harvest corneal tissue and collect blood for serology;
- iv. Ensure safe transportation of tissue to the parent eye bank

Eye Bank (EB)

Eye Bank is an organization that should:

- i. Be registered under "The Transplantation of Human Organs, Act 1994";
- ii. Provide a round-the-clock public response system for eye donation;
- iii. Co-ordinate with donor families and hospitals to motivate eye donation;
- iv. Harvest corneal tissue;
- v. Process and evaluate the collected tissue and blood;
- vi. Distribute tissue in an equitable manner to organizations having capacity for corneal transplantation;

- vii. Ensure safe transportation of tissue.
- viii. Conduct public awareness programmes on eye donation.

Corneal Transplantation Centre (CTC)

Corneal Transplantation centre is an organization in Government or Voluntary Sector that should:

- i. Be registered under "The Transplantation of Human Organs, Act 1994";
- ii. Have capacity to perform corneal transplantation;
- iii. Have facilities and equipments required for corneal transplantation;
- iv. Have trained/experienced eye surgeons capable of performing corneal transplantation.

Conditions for eligibility:

- i. Eye Bank can be a Government or Voluntary Sectors and should not be run for profit to any individual or group of individuals;
- ii. In case of Voluntary Sector, the Organization must be registered under the Society's Registration Act of 1860 or any other statute;
- iii. Its work and financial position should be satisfactory and it should not be involved in any corrupt practices;
- iv. The Eye Bank (EB)/ Cornea Transplantation Centre (CTC) should be registered under "The Transplantation of Human Organs, Act 1994";
- v. It should have its own infrastructure to carry out the Eye Banking activities;
- vi. The Eye Donation Center (EDC)/Eye Bank (EB) should have good track record and should have collected not less than 25 Eye balls in the previous year;
- vii. The organization should have the necessary minimum staff as mentioned below:

Dr. (Mrs.) R. Jose
Dy. Director General (O)
Tel:-011-23061594
Email- ddgo@nb.nic.in

Note:

For setting up of an Eye Donation Center (EDC)/Eye Bank (EB) in the State Govt./Central Govt. Institutions and

established eye hospitals in voluntary sector, condition No.6 is not mandatory.

Eye Bank Network

Corneal Tissues collected by Eye Donations are precious and scarce. Steps should be taken to establish network between Eye Donations Centres, Eye Banks and Keratoplasty Centres with good communication system to reduce loss of time and tissue. A typical network is given below:

Minimum Number of Personnel	EDC	EB	CTC
Ophthalmic Surgeons (Full time/ on Panel)	1	1	1
Ophthalmic Technician	1	1	1
O.T. Technician/Nurse	-	-	1
Social worker/Health Educator/Clerk	1	2	-
Driver	1	1	-
Helper cum watchman	1	1	-

Pattern of Assistance

Eye Donation Center /Eye Bank in Government/ Voluntary sector fulfilling all the above-mentioned conditions and seeking financial assistance under National Programme for Control of Blindness, the Govt. Institutions/ NGOs should apply in prescribed application form to concerned District Blindness Control Society (DBCS). The proposals would be examined by DBCS and forwarded to concerned State Blindness Control Society (SBCS).

Grants-in-aid approved for the 10th Plan is given below:

Eye Bank

Non-recurring assistance up to Rs.10.00 lakh for setting up/strengthening of Eye Banks for the following items:

S.No.	Item
1	Slit Lamp Microscope
2	Operating Microscope with camera attachment
3	Specular Microscope
4	Laminar Flow
5	Serology Equipment
6	Instruments for corneal excision and Enucleation including containers
7	Autoclave
8	Transport facility (one 4 Wheeler/One 2 Wheeler)
9	Refrigerator
10	Computer & Accessories
11	Telephone Line
12	Air-Conditioner
13	Renovation, Repair, Furniture & Fixtures

Eye Donation Centres

Non-recurring assistance up to Rs.1 lakh for setting up/strengthening of Eye Donation Centre for the following items:

S.No.	Item
1	Refrigerator
2	Enucleation Set
3	Containers for corneal sets
4	Corneal sets
5	Autoclave
6	Device and/or material for Health Education activities.
7	Vehicle (Two wheeler)

(v) Recurring grant-in-aid to Eye Banks and Eye Donation Centres

DBCS has been empowered to monitor functioning of eye banks, collection and utilization of donated eyes and providing grant-in-aid to Eye Banks and Eye Donation Centres for recurring assistance.

GIA to Eye Banks

As per revised pattern of assistance, Rs.1000 per pair of Eyes collected may be provided to eye banks on the basis of eye collected. This grant can be utilized on the following items.

- Preservation Material (like MK Media) for preserving donor Eyes and for the purchase of reagents, chemicals, kits and other consumables required for preservation and testing of eyes;
- Payment of honorarium to surgeon, technician, social worker, etc.
- Expenditure on remuneration, transportation/POL, maintenance of vehicles etc. or hiring of vehicle for collection of Eyes.
- Rent of telephones, postage and other means of communication.
- Other expenses such as wreaths, garlands, stone eyes etc.
- Maintenance of Eye Bank equipment.

The grant-in-aid is released on the basis of actual number of donated eyes, on a reimbursement basis through DBCS.

GIA to Eye Donation Centres

As per revised pattern of assistance, Rs.500 per pair of Eyes collected may be provided to eye donation centres on the basis of eye collected. This grant can be utilized on the following items:

- a) Preservation Material (like MK Media) for preserving donor Eyes, container for corneal sets, etc.
- b) Payment of honorarium/remuneration to Surgeon, technician, social worker, etc.
- c) Expenditure on transportation/ POL, maintenance of vehicles etc. used for collection of Eyes.
- d) Rent of telephones, postage and expenditure on any other means of communication.

- e) Other expenses such as wreaths, garlands, stone eyes and consumables, etc.

The grant in aid will be paid to the Eye Donation Centre through the respective Eye Bank and/or District Blindness Control Society of their District on the basis of donated eyes.

Note:

Normally Eye Donation Centres are expected to deliver Eye balls to the Eye Bank/ C.T.C. The District Programme Manager (DBCS) should ensure that Eye Donation Centres/ Eye Banks are not paid twice for the same pair of Eyes.

Harvesting of Fascia Lata

Ashok K. Grover, MD, MNAMS, FRCS, Zia Chaudhuri, MS, MNAMS, FRCS, Shaloo Bageja, DNB

Autologous grafts have the advantage of being recognized as “self” by the body and hence incite minimum reaction. They form an ideal material for grafts because of their being strong, biologically inert (causing minimum inflammation), and readily available. Fascia lata is one of the most common autologous grafts being used in all branches of ophthalmology because of its adherence to all the qualities mentioned above.

Surgical Anatomy

The fascia lata envelops the muscles of the upper leg. Laterally, it coalesces to form a thicker ileotibial band, just under the subcutaneous tissue, which runs from the iliac crest to the tibia. It is narrow distally and much broader proximally. Several muscles in the upper leg have fibrous attachments to this band. It is important to remember this anatomical configuration and not disrupt the longitudinal integrity of the ileotibial band while harvesting fascia lata.

Because the band is broader proximally, this is the ideal place to obtain the largest sheet of fascial tissue. More distally, the band is narrow and thicker and more amenable to harvesting of robust, thin strips.

Indications for harvesting fascia lata

1. *Neurosurgery*: Large sheets of the fascia may be used as a dural substitute in neurosurgical procedures.
2. *ENT*: Pieces of the Fascia lata can be used to obliterate the frontal sinus.
3. *Obstetrics and Gynecology*: Used for pelvic reconstructive surgeries
4. *Cardio-thoracic surgery*: Used as a pericardial substitute in open heart surgery
5. *Gastro-intestinal surgery and traumatology*: Used to reconstruct the abdominal walls.
6. *Ophthalmology*
 - a. Thick, robust strips can be used as material for performing a frontalis sling surgery.
 - b. Small strips can be harvested to provide an anchor to tighten the eyelid to the periosteum in paralytic ectropion.

- c. Fascia lata sheet can be used to wrap a hydroxyl-apatite implant after enucleation
- d. Small strips can be used to provide an autologous anchor for tethering the globe to the medial wall periosteum in third nerve palsy.

Contra-indications for harvesting fascia lata

1. Previous traumatic or surgical injury to the fascia lata.
2. Infection at the recipient site (the graft will fail and having used the fascia lata once from one donor site, that site cannot be used again to harvest the fascia).

Surgical Technique

1. *Pre-operative preparation and counseling*
 - a. If a longitudinal incision is planned, the chances of having a scar on the lateral aspect of the thigh should be explained to the patient.
 - b. Through a thorough history and physical examination, any previous trauma to the donor site should be ruled out.
 - c. Potential complications in the form of an acute muscle hematoma, seroma requiring serial aspiration or drainage, prolonged post-operative pain, difficulty in walking for a couple of weeks, muscle herniation and infection at the donor site should be explained to the patient.
2. *Instrumentation*
 - a. A minor surgical instrument set comprising of a couple of retractors, a long bladed scissors, a bipolar cautery and long forceps are required.
 - b. Crawford's fascia lata stripper may be included in the tray if available. As the classically described technique for harvesting fascia lata from the lateral thigh was a long, 10 cm incision, it was often rejected by patients on the grounds of being unacceptable cosmetically. The use of the stripper allowed harvesting from a relatively smaller incision. The authors have been using a small incision (2.5 cm) for the harvesting of fascia lata from the lower thigh in the line joining the anterior superior iliac crest and the lateral tibial condyle, without the help of this expensive instrument for the past 9 years. For the past 2 years, they have performed a further modification of the technique by virtue of which they have now been able to harvest the tensor fascia through a small upper thigh incision (10 mm), which

Department of Ophthalmology

Sir Ganga Ram Hospital,
New Delhi

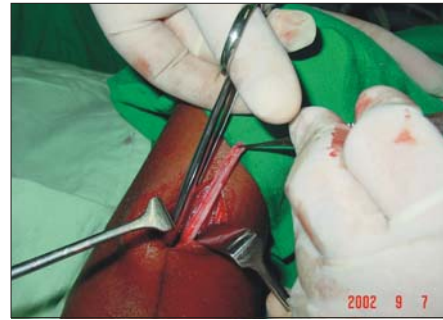
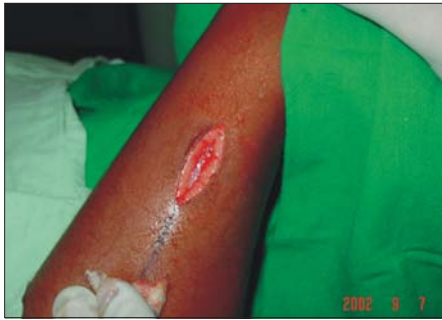
Fig. 1A & 1B: A lower thigh small incision showing exposure of the fascia lata and the subsequent harvesting with a long-bladed scissors.

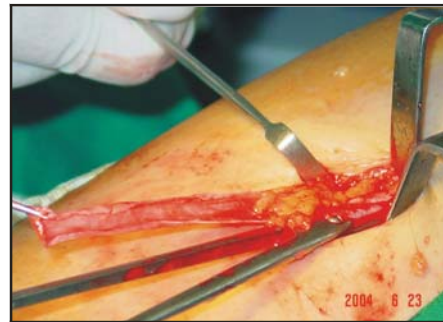
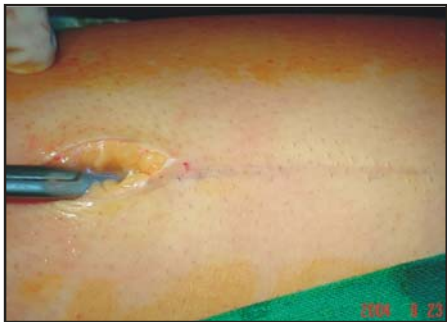

Fig. 2A & 2B: An upper thigh small incision being given to harvest the fascia lata under direct vision. Note the greater extent of fat present in the upper thigh.

is far more acceptable cosmetically. The intraoperative and postoperative complications, both subjective and objective are far less with these small incisions. The patient is rehabilitated almost immediately and no major complications have been seen in the past decade in more than 50 patients in whom the harvesting was performed by this technique.

- c. The procedure is performed under all sterile conditions. It is important to have all materials for a standard preparation of the case in the form of 10% povidone iodine, 1% lignocaine with 1:100,000 epinephrine, split drapes, antibiotic ointments and elastic bandages.
- d. It is important to remember that anesthesia tubings, IV lines, arterial lines, and blood pressure cuffs should not run along the side of the patients such that it obscures access or hinders visualization of the upper lateral leg.

3. Operative Procedure

After appropriate preparation, the patient's leg is placed in a position of adduction at the hip joint and flexion



Fig. 3: The harvested fascia lata sheet may subsequently be cut into strips of adequate length and width outside on a wooden board. In this case, the strips were cut into 4 parts of 10 cm X 3 mm each to be used subsequently as a slinging material for ptosis surgery in a case of severe congenital ptosis requiring frontalis slinging.

and lateral rotation at the knee joint. It helps to elevate the ipsilateral hip on a small pillow to improve access to the upper lateral thigh.

a. Harvesting of a sheet of fascia through a longitudinal incision (Classical Technique)

- i. A longitudinal incision is made along the upper thigh, the center of which lies over the junction of the upper and middle one third of the upper leg.

- ii. The incision is carried down to the ileo-tibial band of the fascia lata. If fat is also to be dissected and harvested, the cautery should be minimally used.

- iii. After the fascia is exposed, a medial and a lateral longitudinal incision is made in the fascia according to the pre-determined width, the distal transverse incision is made, and the fascia is removed taking care that the underlying muscle is not violated in

any way.

- iv. The wound is closed in 2 to 3 layers over a 7 to 10 mm fully perforated drain
- b. Harvesting of a sheet of fascia lata through a small incision longitudinal incision (Author's modification)

- i. A longitudinal incision is marked in the line joining the anterior superior iliac spine and the lateral tibial condyle. A 2.5 cm incision is given at the junction of the middle and the inferior 1/3rd of this line. The exposure is taken to the level of the fascia lata. The surrounding fat is retracted back, the medial and the lateral horizontal incisions are given under vision (good retraction is required), and the final transverse incision is given with the help of a long-bladed scissors and the fascial sheet is removed. (Figure 1 A and 1 B)

- ii. For the past 2 years, the 2.5 cm incision is given at the junction of the upper and middle 1/3rd of this line, so as to give the patient a more cosmetically acceptable scar. Through the extent of fat encountered in the upper thigh is more, there were no other intra-operative or post-

- operative problems faced by the authors with the adaptation of this technique. (Figure 2 A and 2 B)
- iii. The harvested sheet can be cut into the required strips over a wooden board (Figure 3)
 - iv. The incision in both cases is closed in 2 layers. We have not used a suction drain in any case.
 - v. The smaller size of the incision, the immediate post-operative rehabilitation and absence of a visible scar post-operatively makes this procedure an excellent, inexpensive and easily available modification in a developing country like ours, where fascia lata strippers may not be available in every set-up. The use of this modification may in fact be better than the use of a fascia lata stripper because it maintains the physical integrity of the ileo-tibial band due to the longitudinal nature of the incision.
- c. Harvesting of a long thin strip of fascia lata with a fascia lata stripper
 - i. A horizontal incision approximately 4 cm in length, 8 cm above the knee is made over the ileo-tibial band and the incision carried down to the fascial layer.
 - ii. A 1.5 cm transverse incision is made in the fascia and a 2-0 mersilk suture is placed in the proximal edge to assist in threading this through the fascia lata stripper.
 - iii. The fascia lata stripper is engaged and with the stripper held as close to the leg as possible, it is pushed superiorly while gentle tension is held on the silk suture pulling the fascia through the stripper. The fascia stripper is triggered, which cuts the fascial strips proximally. These may then be harvested as required.
 - iv. The incision is closed, and a pressure dressing is applied to the lateral leg and a drain may be inserted
4. *Post-operative care*
 - a. If a drain is placed, it can be removed in about 1 day if the drainage is below 30 cc of blood.
 - b. Elastic pressure dressings may be used in the early post-operative period.
 - c. Though most patients do complain of mild post-operative pain and difficulty in walking in the first post-operative week, it usually does not cause significant morbidity

The authors have been very happy with the results of their modification of the classical technique of harvesting fascia lata through a longitudinal incision without the use of a fascia lata stripper.

Microincision Lenses

Ashok Garg, M.S, Ph.D, ADM, FRSM,

The efficacy and predictability of microincision cataract surgery and refractive lens exchange has now been established (1), but as far as IOLs are concerned, they'll need time to raise up to the standards of conventional intraocular implants. The main issues concerning these IOLs are incision size, insertion technique, instruments and stability in the eye.

Lenses for microincision (less than 2mm) cataract surgery are the future of IOL technology, although more research is needed to improve the current microsurgery implants and to reach the standards of conventional implants.

Currently, there are four types of lenses available for microincision surgery in 2004 in Europe.

After a presentation of the four IOLs it will be interesting to describe the manipulation, final incision size, stability, side effects and rate of posterior capsule opacification (PCO).

Description and design of the IOLs

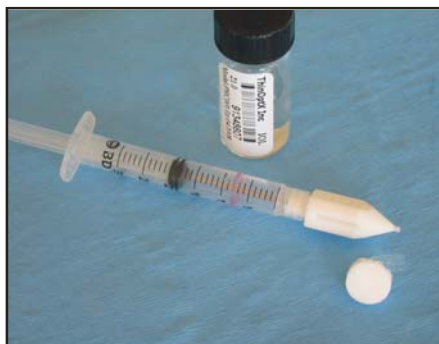Ultra Choice 1.0

The ThinOptX Ultra Choice 1.0 is perhaps the most innovative of the batch.

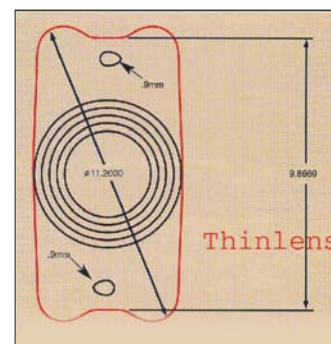
The optic diameter is 5.5 mm, and the total diameter is 11.2mm.

The material is 18% hydrophilic acrylic. The optic is 400µm and the haptic as thin as 50µm. This is in contrast to the traditional lenses, which have a central thickness from 1.0mm to 1.2mm depending of lens power (2).

The design is the real innovation of this lens. While one surface retains a continuous curvature as traditional lenses, the second surface (anterior) is divided into a series of concentric 50 µm high rings, with a slightly different curvature at each step. When light rays enter the eye, the design of the back surface of the lens directs them to focus on the same point in the retina, with the object to reduce spherical aberrations (3).



Ultra Choice 1.0
Injector and packaging



Ultra Choice 1.0
sketch

Acriflex 46 CSE

The Acrimed Acriflex 46 CSE is a 25% hydrophilic acrylic IOL with hydrophobic coating, a 5.5-mm biconvexe optic and a 11mm total diameter. It is designed to be implanted with a special self-blocking capsular tension ring.

It has zero angulation between optic and haptics.

However we cannot be sure that the connection between the both ends will be effective (difference of capsular bag size).

Acri.Smart 46S

Similar to the Acriflex, the Acri.Tec Acri.Smart 46S is made of hydrophilic acrylic material with hydrophobic coating. It has a 6-mm biconvexe optic and a 11mm total diameter with zero angulation (4-5).

Both optic and haptics have a square-edge design, which should prevent posterior capsule opacification.

SlimFlex

The Physiol SlimFlex IOL is made of 26% hydrophilic acrylic material. It has a 6mm biconvexe optic and a 10.5mm total diameter (6-7).

Unlike the three others IOLs it has not a plate haptic design but a 360° square edge optic, four haptics and 5° angulation between optic and haptics.

Since November 2004 this IOL is available in Europe.

Manipulation, injection and final incision

All these IOLs have to be injected through a microincision without introduction into the corneal channel. The final incision is generally wider than it could

Garg Eye Institute & Research Centre
235, Model Town, Dabra Chowk,
Hisar - 125005

be describe by the companies.

As a matter of fact the final incision could be find by the formula:

$$3.14 \times \text{diameter of cartridge} / 2.5$$

For a final incision size less than 2mm you have to develop a cartridge outer diameter smaller than 1.6mm and an inner diameter of 1.3mm.

Ultra Choice 1.0

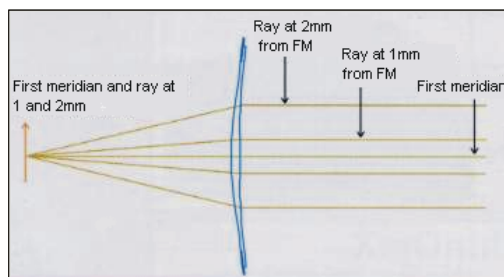
Thanks to its specific design, with a very thin 400µm optic and 50µm plate haptic, the lens can be rolled into the cartridge and injected through an incision of less than 2 mm.

Acriflex 46 CSE

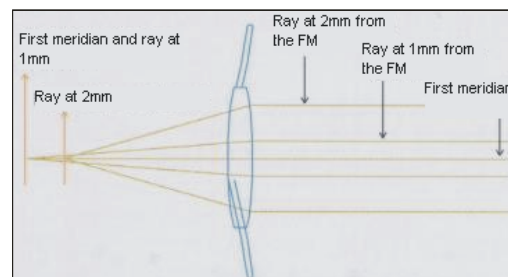
The ring is inserted in the capsular bag, and once it is positioned, the lens is injected through the same incision. We can use a disposable Ophtec injector, which allows us to implant the lens through an incision of slightly more than 2 mm.

Acri.Smart 46S

The Acri.Smart is easy to handle because of the



Ultra Choice 1.0



Standard IOL Biconvexe

packaging (IOL holder). However, this material also caused some problems during the insertion process as implantation maneuvers created marks on the delicate surface of the IOL even when using an injector.

To avoid this problem you must implant the lens with a reusable injector (Acri.Shooter). When loading the lens into it, push it slightly into the cartridge tip rather than inserting it onto the loading deck. In this way, there is no marks on the surface.

SlimFlex


The lens can be injected through an incision of 2.2 to 2.3 mm. The manufacturer is working on a redesign of the lens to be injected through a smaller incision (below 2mm).

It is a very easy IOL for an implantation without any post injection marks.

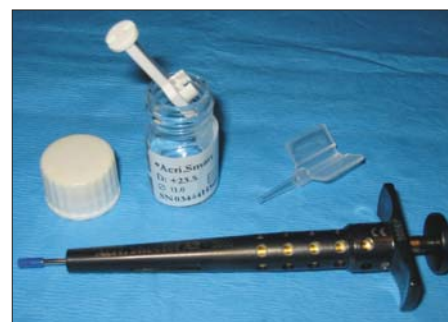The new version of the lens will be pre-loaded in a cartridge. This will excuse to manipulate the lens before implantation.




Injector Easy Pack



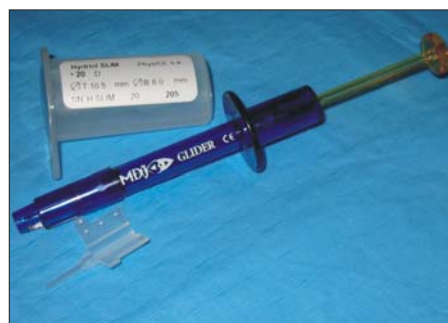Acriflex sketch



Injector Acri Shooter



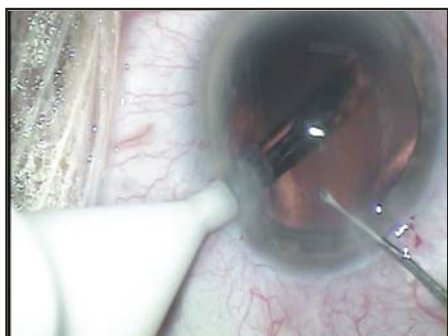
Acri Smart 46S sketch



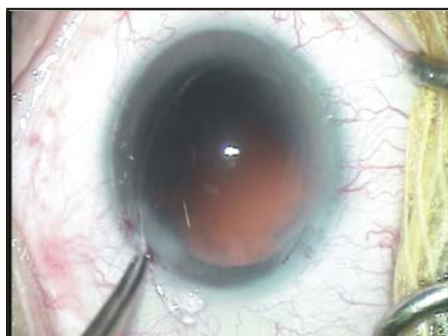Injector MDJ



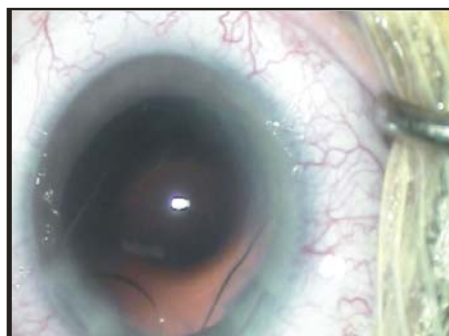SlimFlex posterior view



Thinoptx injection



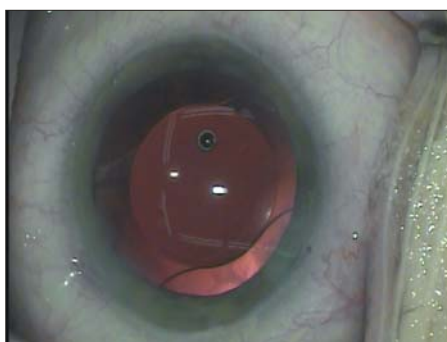**Ultra Choice 1.0
Capsular ring injection**



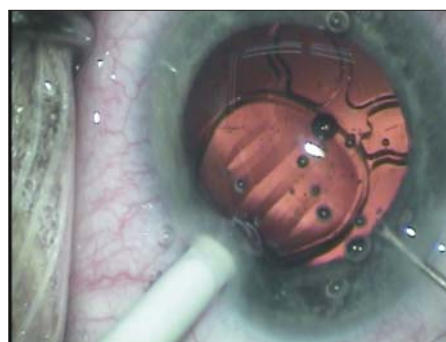
Acriflex 46 CSE



Acrismart injection



Acri.Smart 46S



Slimflex injection

Stability, side effects and rate of PCO

One-piece, plate haptic IOLs fixation have recently raised some concern, and several studies have shown the advantages of three-piece acrylic or silicone lenses with PMMA loops. One-piece, plate haptic lenses are more easily decentered, dislocated and subluxated, especially after YAG capsulotomy (8-9). Refraction tends to be less stable, and studies have shown that the lenses leave more space for lens epithelial cell proliferation and posterior capsule opacification (10).

Ultra Choice 1.0

This IOL is very stable in the bag. However some patients may complain about halos (concentric zones) and glare (3).

We notice also early PCO. It is not amazing, as this lens presents a plate haptic design and a very thin optic without square edge.

In fact we have excellent result for patients who are suffering of macular diseases, probably because they focus all the light rays at one point upon the retina.

Acriflex 46 CSE

The combination with a capsular tension ring makes this lens suitable for complicated cataract cases and weak zonules. The ring stabilizes the lens capsule during IOL

implantation, decreases capsular folds and improves IOL centration but does not avoid the tilting of this very thin lens. This phenomenon is frequently observed in the postop surgery.

Acri.Smart 46S

This IOL remains stable and well centered in the bag during the first months after the surgery.

In accordance with the publications about plate haptic IOL we need time to be sure that it never be dislocated.

The whitening of the IOL after implantation when the Acri.Smart is stored in a too cold room before surgery has not be underlined.

It is a reversible phenomenon which remains surprising if you are not aware of it.

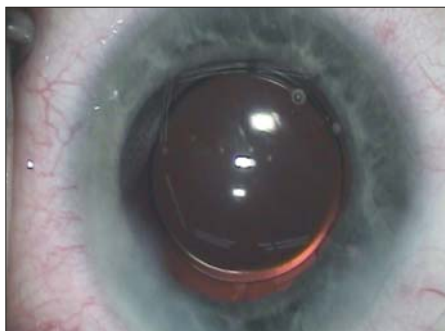SlimFlex

In the bag, the lens unfolds easily and consistently and has a firm hold because of the four arched contact points of the haptics.

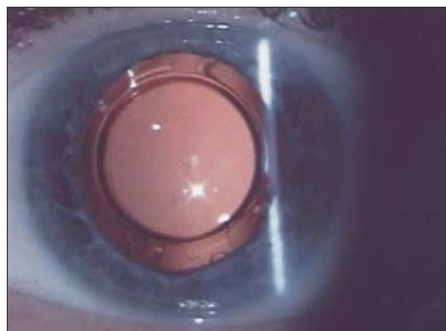
The four-point haptic design guarantees better centration and better long-term stability of the lens.

The injection is very easy without any marks or deterioration of the optic.

The acrylic material, 6mm optic, 360° square edge with four haptics and 5° angulation are the main points which



SlimFlex



SlimFlex 12 months post-op

should avoid or delay the PCO with less postoperative intraocular lens position change (11-12).

Also the anterior capsular opacification (ACO) will be significantly lower with haptic angulation (13-14).

In conclusion

Lenses for microincision will "never" be three-piece lenses with stiff PMMA haptics. In order to be so thin and foldable, they will always be one-piece, but we believe that in the future the SlimFlex will be the IOL of choice because of its haptic design. Further developments will lead to the improvement of insertion devices and to the implantation of these lenses through even smaller incisions.

References

1. Fine H, Hoffman RS, Packer M. Optimizing refractive lens exchange with bimanual microincision phacoemulsification. *J Cataract Refract Surg* 2004; 30:550-554
2. Apple DJ, Auffarth GU, Peng Q, Vissesook N. Foldable Intraocular lenses; evolution, Clinicopathologic correlations, and complications. Thorofare, NJ, Slack, 2000
3. Dogru M, Honda R, Omoto M, Fujishima H, Yagi Y, Tsubota K. Early visual results with the rollable ThinOptx intraocular lens. *J Cataract Refract Surg* 2004; 30:558-565
4. Koch R. Cataract surgery through a 2.0mm incision. Results of bimanual phacochopt technique and acrylic IOL implantation. *Symp Cataract Refract Surg*, San Francisco 2003
5. Wehner W. Clinical Results with the Acri.Smart IOL implanted through a 1.4mm incision. *Symp Cataract Refract Surg*, San Francisco 2003
6. Lesieur G. MICS and new IOLs. *Symp SAFIR*, Paris 2004
7. Lesieur G. IOLs for MICS need improvement. *Ocular Surgery News* 2004;22:6-8
8. Faucher A, Rootman DS. Dislocation of a plate haptic silicone intraocular lens into the chamber. *J Cataract Refract Surg* 2001; 27:169-171
9. Dick B, Schewnn O, Stoffelns B, Pfeiffer N. Late dislocation of a plate haptic silicone lens into the vitreous after ND:YAG capsulotomy. A case report. *Ophthalmology* 1998;95:181-185
10. Abhilakh Missier KA, Nuijts RM, Tjia KF. Posterior capsule opacification: silicone plate-haptic versus Acrysof intra ocular lenses. *J Cataract Refract Surg* 2003; 29:1769-1574
11. Petternel V, Menapace R, Findl O, Kiss B, Wirtitsch M, Rainer G, Drexler W. Effect of optic edge design and haptic angulation on postoperative intraocular lens position change. *J Cataract Refract Surg* 2004; 30:52-57
12. Nishi O, Nishi K, Akura J, Nagata T. Effect of round-edged acrylic intraocular lenses on preventing posterior capsule opacification. *J Cataract Refract Surg* 2001; 27:608-613
13. Schimdbauer JM, Escobar-Gomez M, Apple DJ, Peng Q, Arthur S, Vargas LG. Effect of haptic angulation on posterior capsule opacification in modern foldable lenses with a square, truncated optic edge. *J Cataract Refract Surg* 2002; 28:1251-1255
14. Werner L, Pandey SK, Escobar-Gomez M, et al. Anterior capsule opacification; a histopathological study comparing different iol styles. *Ophthalmology* 2000; 107:463-471

Where is my copy of DOS Times?

Dear DOS members, anyone who could not receive DOS Times from the month of October, 2005 onwards.

Please Contact:

President DOS : Dr. NOSHIR M. SHROFF

or

Secretary DOS : Dr. HARBANSH LAL

**Room No. 2225, 2nd Floor, New Building, Sir Ganga Ram Hospital,
Rajender Nagar, New Delhi - 110 060 Ph.: 55705229,52252225**

Email : dosonlin@vsnl.net

Contemporary Laser Photocoagulation Systems for Diabetic Retinopathy

Tinku Bali, MS, FRCS, H.K. Tewari, MD, S.N. Jha, MD,
Amit Khosla MD, Neeraj Manchanda, DOMS, DNB

The treatment of diabetic retinopathy has evolved dramatically over the past century. Today, laser photocoagulation has replaced xenon arc photocoagulation, and a spectrum of wavelengths is available to treat the retina.

Melanin, hemoglobin and macular xanthophyll are the three principal chorioretinal optical absorbers that determine laser effect. Melanin which is present in the retinal pigment epithelium and choroid is the most effective absorber across the entire visible optical spectrum. Its absorption decreases slowly with increasing wavelength. Thus, longer laser wavelengths such as diode infrared (810 nm) produce deeper, less prominent lesions than argon (514 nm) or Frequency doubled YAG (532 nm) green lasers. Hemoglobin is the next most efficient absorber of optical energy. Its absorption also generally decreases with increasing wavelength, although there are two peaks in the light absorption spectrum of oxyhemoglobin (542 nm, green; 577 nm, yellow)

Xanthophyll in the inner and outer plexiform layers of the macula is the least effective of the three optical absorbers. Argon blue-green laser (488 nm) was used for the DRS study but was subsequently replaced by the argon green laser in the 1980s because of its potential retinal phototoxicity and the fact that it could cause direct damage to the neural retina when absorbed in macular xanthophyll.

ARGON LASER - Argon green, which emits at 514 nm, was, till same years back the most commonly used wavelength due to its excellent absorbance by haemoglobin and retinal pigment epithelium. Two significant disadvantages remain with the Argon laser. First, is its relatively low efficiency, making it necessary to provide a large amount of electric power. Second, its primary working component, the plasma tube, wears out, necessitating periodic replacement of the most costly component of the laser. Thirdly, the most compact of the newer systems is also quite heavy, weighting in the region of 30 kg.

Frequency doubled Nd: YAG lasers are now available with high efficiencies and sufficient power to provide an alternative to argon lasers. This laser is 3 to 5 times more efficient than the Argon laser and the only part that requires replacement is a relatively inexpensive krypton arc lamp. *The frequency doubled Nd:YAG laser has overshadowed the Argon laser and is likely to play a major role in retinal photocoagulation in the near future.*

FD YAG LASER: A frequency-doubled YAG laser is a solid-state laser system that produces a continuous green monochromatic laser beam of 532 nm by doubling the frequency of a neodymium-YAG laser (wavelength of 1064 nm) on passing it through a potassium-titanyl-phosphate (KTP) crystal. It has a tissue effect similar to the argon laser. In theory, the longer wavelength of the solid-state laser offers the advantages of less scattering in ocular media, higher absorption by oxyhemoglobin, and less absorption by macular xanthophyll than the 514-nm wavelength of the regular green argon laser. In addition, FD-YAG green laser also has a high ratio of oxyhemoglobin to reduced hemoglobin absorption for treating active fibrovascular tissue through thin overlying hemorrhage. The solid-state laser has impressive technical advantages: it contains no argon-ion gas tube that wears out and is expensive to replace; it is much more power efficient, and thus considerably smaller and compact; it is sturdier and easily movable; it does not require external cooling and it uses a 220-V monophasic alternating current. The minimum maintenance requirements and low energy consumption make this laser a popular choice.

DIODE LASER: Solid state diode laser (810 nm), have a longer wavelength and therefore excellent penetration. The longer wavelength laser rays are scattered less in intraocular transit than green light, so they have an advantage in the treatment of patients with hazy ocular media (eg nuclear sclerotic cataracts) or mild vitreous hemorrhages. It can also be delivered through diabetic pre retinal membranes without contracting them. During treatment the patient is not irritated by bright flashes as the light is invisible. However the deeper penetration results in less visible burns on the retina and potentially more pain. When treating eyes with diffuse diabetic macular oedema (DME) close to the foveal avascular zone, the longer wavelength laser, may have an advantage since the burns affect deeper layers with relative sparing of the

Vitreous Retina Unit

Department of Ophthalmology,
Sir Ganga Ram Hospital,
New Delhi

inner neurosensory retina, which in turn, may reduce the degree of perifoveal scotomas usually experienced by patients undergoing laser photocoagulation for DME

Micropulse diode laser therapy which is an option in these lasers may have significant advantages over conventional retinal laser photocoagulation since it is theoretically less likely to produce unwanted retinal or choroidal thermal damage. The diameter of a RPE cell is ~10 μ m. A pulse duration of 0.1 ms (termed micropulse) corresponds to a thermal diffusion distance of 10 μ m in ocular tissue. Thus, a pulse duration of less than 0.1 ms should have no thermal effect on structures 10 μ m or more from the RPE cell (e.g., photoreceptors and choroidal melanin granules) and may be associated with a lower incidence of complications such as symptomatic scotomata and CNV formation. Theoretical considerations and early clinical results indicate that micropulse laser may offer an equally effective and safer treatment option for patients with diabetic retinopathy. However resolution of edema may be slightly prolonged and may require 1 or 2 additional treatments compared to eyes previously treated with shorter wavelengths and more visible burns.

The diode lasers are low cost, have low power requirements and are often more portable and smaller than other types of lasers.

Contemporary Laser Systems

The size of laser photocoagulators has evolved over the past 25 years from large console models to those which can now be placed on top of a desk. Today's laser photocoagulation systems offer a diverse, flexible platform to treat diabetic retinopathy and other retinal disorders. Several photocoagulation systems incorporate multiple lasers at multiple wavelengths, allowing the ophthalmologist to easily switch back and forth to tailor treatment for each patient. Delivery systems are equally diverse, and many systems have adapters for the slit lamp and indirect ophthalmoscope, as well as endoprobes for surgical endophotocoagulation during vitrectomy.

The ophthalmologist also may consider portability, power requirements, digital displays, voice output, type of foot pedal, and other accessories for customizing their own laser photocoagulation system.

The various contemporary retinal photocoagulation systems available include the following

A. VISULAS – Carl Zeiss (FIG. 1)

- ♦ **Laser** – 532 nm (Frequency doubled Yag), solid state green laser, continuous wave
- ♦ **Ergonomics** – Easy to use, portable
- ♦ **Low power consumption** - Plugs into any standard

power outlet. With low power consumption, the “diode on demand” technology guarantees a long service life.

- ♦ The brightness of the antireflective touchscreen can be adjusted in steps and all parameters are visible with striking clarity against a dark background. The control panel is detachable for greater ease of use.
 - In the ophthalmologist's office with the laser slitlamp LSL 532s and instrument table
 - In mobile use: Fast and universal attachment on several diagnostic slitlamps
 - In the operating room with endoprobes and laser indirect ophthalmoscope.

Visulas YAG III COMBI

This is a combination of the individual instruments VISULAS YAG III and VISULAS 532s - the full performance of each individual laser being fully maintained. The system is extremely compact and space-saving:

B. EYELITE OPHTHALAS 532-Alcon Laboratories (FIG. 2)

- ♦ Laser – 532 nm (Frequency doubled Yag), solid state green laser, continuous wave
- ♦ Spot size – 50 μ to 1000 μ
- ♦ Exposure time - 0.01 to 2.0 secs
- ♦ Power – Maximum output 1700 μ on the cornea
- ♦ Ergonomics – Though portable it is a trifle heavy at 16kgs. compared to other light weight lasers available.
- ♦ Air cooling - The special Thermal Electric Cooler maintains cooling in a high-temperature environment and enables quiet, sustained operation.
- ♦ Low power consumption - Plugs into any standard power outlet.
- ♦ Offers many delivery options for slit lamps, indirect ophthalmoscope and endophotocoagulation units.
- ♦ Features an LIO system that is modified with design enhancements. The illumination beam and aiming beam are on the same path rather than being offset from each other. Its unique 23 spot size feature allows users to adjust spot size and make it smaller to increase the intensity of the burn if necessary without modifying power.

C. IRIDEX

Various Laser Treatment Protocols are available with this laser

1. Continuous-Wave (CW Pulse) Photocoagulation

A single or repetitive continuous-wave, laser pulse



Fig. 1: VISULAS 532 LASER



Fig. 2: EYELITE 532 LASER



Fig. 3: OCULIGHT SLX DIODE LASER

delivered as traditional (visible endpoint) photocoagulation

Laser Consoles:

- Infrared (810 nm)
- Green (532 nm)

2. MicroPulse Photocoagulation

A minimum intensity (sub-clinical, retinal-sparing, invisible endpoint) photocoagulation protocol that uses a train of repetitive, very short, very low energy laser pulses to limit and confine laser damage to the minimum level sufficient to trigger the biological response needed for therapeutic effects while leaving the majority of adjacent tissue unaffected.

Laser Consoles:

Pulse CW	30 ms-9000 ms	
Micro Pulse	100 μ s - 1000 μ s	Duration
	1.0 ms - 10 ms	Interval
Long Pulse	10s - 30 min	

Infrared (810 nm)

3. Long Pulse Photocoagulation

An extended continuous-wave treatment allowing uninterrupted laser exposure up to 30 minutes. Mainly intended for transpupillary thermotherapy (TTT) hyperthermic procedures at low irradiance with large spot size. For choroidal neovascularization (CNV) in AMD, TTT is typically delivered with exposure duration of a least 1 minute and with large spot sizes ranging from 0.8 to 3.0 mm diameter, and extendable up to approximately 6.0 mm with lenses.

Laser Consoles:

- Infrared (810 nm)

Iris Medical IQ 810 Infrared Laser

This laser is designed to perform traditional and Minimum Intensity Photocoagulation (MIP) procedures in the office OPD and operating room settings. It has a unique 'Smart Control' Footswitch which can be used as an alternative to the standard footswitch and allows laser activation as well as increment and decrement of power.

Oculight GL Green (532 NM) Laser

Using the latest in solid-state technology, these lasers emit true continuous-wave green light at 532 nm. Their multiple delivery device options maximize versatility, compact size allows easy transportation between offices, and advanced design minimizes routine laser maintenance.

Oculight SL/SLX Infrared (810 NM) Lasers (FIG 3)

The OcuLight family of infrared laser photocoagulators includes the OcuLight SL and OcuLight SLx models. These diode lasers serve as a single laser source for multiple delivery devices and applications, require no regular maintenance or special electrical/cooling, and allow easy transport with their compact design. (Weight =6.3kg).

The OcuLight SLx is now available with Tri-Mode capability to maximize treatment flexibility offering CW-Pulse (for traditional visible endpoints), MicroPulse (for subclinical invisible endpoints), and LongPulse treatment options (for TTT).

Oculight Symphony (FIG 4)

The OcuLight Symphony is the first laser delivery system to offer the clinical versatility and convenience of 532 nm, 810 nm and large spot 810 nm in one well-orchestrated device. The OcuLight Symphony is offered in two versions. The first consists of the solid-state 532 nm Ocu-Light GLx and 810 nm OcuLight SLx lasers, a multi-fiber slit lamp adapter, a custom cart, and an integrated slit lamp. The second



Fig. 4: OCULIGHT SYMPHONY



Fig. 5: NIDEK GYC 1000 LASER



Fig. 6: NIDEK DC-3300 LASER

version consists of the GLx and SLx lasers, a multi-fiber slit lamp adapter that adapts to an existing Zeiss 30 slit lamp, and a custom cart.

D. NIDEK

Nidek GYC 1000 (FIG 5)

- ♦ Laser – 532 nm (Frequency doubled Yag), solid state green laser, continuous wave
- ♦ Exposure time - 0.01 to 3.0 secs
- ♦ Power – Maximum output 1700 μ on the cornea
- ♦ Ergonomics - *Claims to be the world's smallest green laser on the market.* This is extremely compact and lightweight (6.7 kg) with a carry handle making it very easy to shift from the clinic to the O.R. without having to put it in a case everytime.
- ♦ Air cooling - Specially designed with silent air cooling. One of the quietest photocoagulators available
- ♦ Low power consumption - a novel ITC (Intellegent thermo control) function reduces the power requirement making it extremely economical.
- ♦ Offers many delivery options for slit lamps, indirect ophthalmoscope and endophotocoagulation units.
- ♦ The user-friendly control panel is detachable from the main unit, providing greater ease of use and convenience. Also, the spot size indication is on the panel itself which is not there in other lasers.

Nidek DC-3300 (FIG 6)

- ♦ Multipurpose delivery allows a broader range of treatment
- ♦ Laser – 808 nm diode, continuous wave
- ♦ Spot size – Adjustable from 100 μ to 3000 μ (for TTT)
- ♦ Exposure time – Adjustable from 0.02 secs to 600 secs (for TTT)
- ♦ Power – Maximum output 2000m W
- ♦ Ergonomics – Lightweight (6 kg) and compact with a carry handle. The small size of the system makes it

easy to move between patient treatment areas as needed.

- ♦ Air cooling – Generates very little heat eliminating the need for a large cooling system, operating noise and air exhaust are minimized.
- ♦ Low Power Consumption - Requires only a standard electrical outlet.

♦ The DC-3300's laser diode has a substantially longer life than Argon or Krypton lasers. Since operational parts in the main console are very few, it offers virtual trouble-free performance as well as high durability and low operating costs.

- ♦ A Full Range of Delivery Options

Combination Lasers

NIDEK Combination Lasers offer the potential for considerable space saving and versatility, ideal in small laser suites or crowded operating environments. "Combination" units may be configured in the field in either a YAG/Diode (DC-3300) or YAG/Green laser (GYC-1000) system.

Maintenance of Laser Devices

The most sensitive and vulnerable part of an ophthalmic laser system is the fiber-optic cable used to couple the laser energy to the delivery device. The fiber is made of glass, and the ends are optically polished to allow maximum laser transmission. The tip of the exposed end of the fiber connector is where the laser energy is focused into the fiber. If there is any dirt or debris on the face of the fiber, the laser energy will vaporize it and cause damage to the fiber face, which will lead to power loss through the delivery device. Eventually, this damage will propagate itself to a point that there is a noticeable change in delivery device performance. Most fiber damage can be avoided if care is taken to keep the fiber face free of any contamination.

Follow these simple steps to ensure a long life of the laser

1. When inserting the fiber face into the front of the laser, be very careful not to touch the tip of the fiber connector to anything.
2. Insert the tip of the fiber connector into the fiber port hole at a slight angle to start, and then push it in. This will ensure that the tip of the fiber does not touch the edges of the fiber port.
3. Replace the protective cap immediately after disconnecting the delivery device to shield the fiber face from damage and contamination.

Epidermal Nevus Syndrome

Navneet Mehrotra MBBS, Sudipta Ghosh DOMS.

Madhu Karna MS, Satya Karna DO, DNB

Introduction

Epidermal nevi (EN) are congenital hamartomas of embryonal ectodermal origin classified on the basis of their main component. The component may be sebaceous, apocrine, eccrine, follicular, or keratinocytic. An estimated one third of individuals with EN have involvement of other organ systems; hence, this condition is considered to be an epidermal nevus syndrome (ENS), which may represent multiple entities. The term organoid nevus may be used to emphasize the admixture of epidermal cells often evident in individual lesions of EN.

Skin manifestations of epidermal nevus syndrome^{1, 5, 6}

Linear sebaceous nevus (Figure 1,2), linear nevus comedonicus, linear epidermal nevus, inflammatory linear verrucous epidermal nevus.

Malignant transformation may lead to:

Squamous cell carcinoma, Basal cell carcinoma, Sebaceous carcinoma, Trichoblastoma, Syringocystadenoma papilliferum, Nodular hidradenoma, Sebaceous epithelioma, Cystadenoma, Eccrine carcinoma, Spiradenoma and Keratoacanthoma.

Ocular manifestations of epidermal nevus syndrome^{1,4}

About one third of patients with epidermal nevus syndrome present with ocular manifestations⁴.

Extension of epidermal nevus to eyelid, conjunctiva and sclera, astigmatism, nystagmus, ptosis, strabismus

blocked tear duct, ectopic lacrimal glands, choristomas^{2,3} (Figure 3-5), calcification in sclera, corneal opacities and pannus formation, bilateral cataracts, coloboma of : lid, iris, choroids and retina, microphthalmia or macrophthalmia, optic nerve hypoplasia, cortical blindness and phthisis bulbi.

Skeletal abnormalities^{5,6}

Bone cysts, bone hyperplasia or hypertrophy (Figure

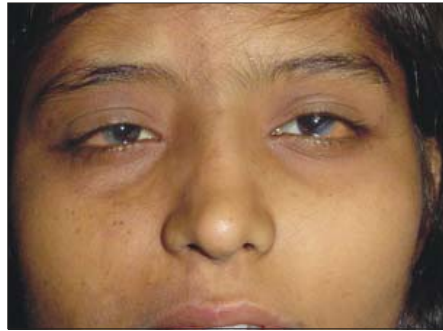

Fig. 1. Linear epidermal nevus on forehead

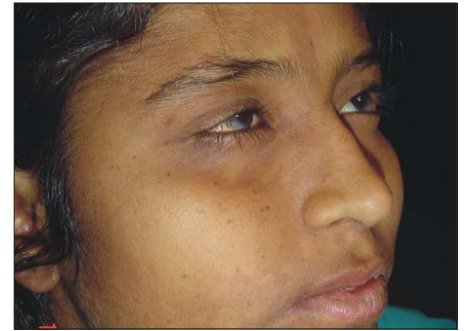

Fig. 2. Side view of linear nevus

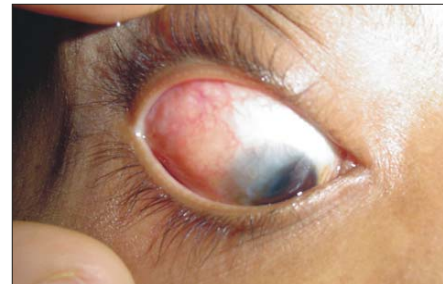


Fig. 3. Choristoma Right eye

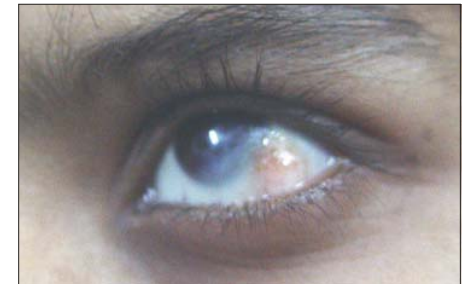

Fig. 4. Choristoma Left eye

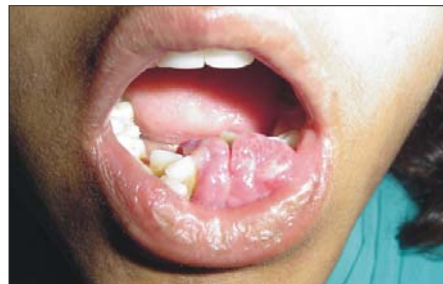

Fig. 5. Gingival hyperplasia

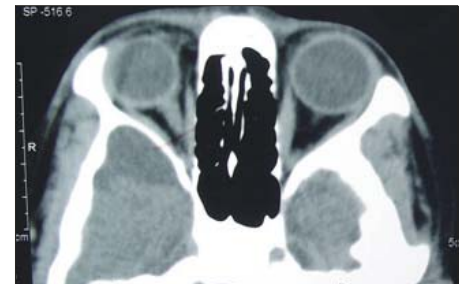


Fig. 6. Axial CT scan showing right temporal arachnoid cyst. Note absence of any calcification of ocular coats

6), chondroblastoma, kyphosis, scoliosis, spina bifida, syndactyly, polydactyly, chinodactyly and vitamin D-resistant rickets

Neurological abnormality^{5,6}

Focal thickening of the calvarium, hypoplasia of the white matter, cortical calcifications, arachnoid cyst (Figure7).

Conclusion

Epidermal nevus syndrome is a rare entity. Knowledge of this condition for an ophthalmologist is important for right diagnosis and timely intervention as scleral calcification leading to visual loss is a known complication and rarely skin lesions can become malignant. This patient was advised a dental check up for the gingival mass and yearly ophthalmic follow up.

References

1. Albert DM, Jakobiec FA, Azar DT et al. Eyelid tumors of Apocrine, Eccrine and Pilar origins. Vol 4 (256): 3405-3430
2. Mansour AM, Barber JC, Reinecke RD, Wang FM. Ocular choristomas. *Surv Ophthalmol.* 1989 Mar-Apr; 33(5):339-58.
3. Garella Manisha; Ghosh B.; Thakar Meenakshi; Nigarn Sonu; Jain Rajeev. Linear Nevus Sebaceus Syndrome With Bilateral Complex Limbal Choristomas and Extraocular Muscle Involvement. *Annals of Ophthalmology*, March 2004, 36(1),59-62(4).
4. Shields JA, Shields CL, Eagle RC et al. Ophthalmic features of organoid nevus syndrome. *Trans Am Ophthalmol Soc.* 1996; 94:65-86; discussion 86-7
5. Sugarman JL. Epidermal nevus syndromes. *Semin Cutan Med Surg.* 2004 Jun; 23(2): 145-57.
6. Vujevich JJ, Mancini AJ. The epidermal nevus syndromes: multisystem disorders. *J Am Acad Dermatol.* 2004 Jun; 50(6): 957-61.